

Case Report

# Timely Surgical Intervention for Absent Pulmonary Valve Syndrome with an Intact Ventricular Septum in a Patient with a Long-Term Survival: A Case Report

Yunyi Zhang<sup>1</sup> , Shuhua Luo<sup>2,\*</sup>, Enping Wang<sup>2</sup>

<sup>1</sup>Department of Anesthesia and Operation Center, West China Hospital of Sichuan University, Chengdu, China

<sup>2</sup>Department of Cardiovascular Surgery, West China Hospital of Sichuan University, Chengdu, China

## Abstract

Absent pulmonary valve syndrome with an intact ventricular septum (APVS with IVS) is a rare congenital heart defect that is associated with a high perinatal mortality. Most fetuses can hard to survive without inotropic support or heart transplantation due to the severe respiratory dysfunction, heart failure and serious infections resulting from tracheobronchial compression and right ventricular dilation. Almost one-third of the patients opted for a termination of pregnancy. The etiology of APVS patients is still unknown. Previous research only noted an enhancement in the long-term survival of APVS with tetralogy of Fallot patients over the past decade. However, the timeliness of surgical intervention and survival status in APVS with IVS patients remains unclear. In our case, we described a 27-year-old patient with a rare combination of the rudimentary pulmonary valve, intact ventricular septum and absent superior vena cava who successfully developed biventricular physiology without any medical intervene. And he received a timely pulmonary valve implantation in our centre to prevent further right ventricular dysfunction. Thus, we highlighted that biventricular circulation can be successfully achieved in this rare subtype of APVS with IVS patients. However, more multicentre studies and lifelong follow-up are required to determine the timeliness for pulmonary valve surgery to avoid over-dilatation of the right ventricle in APVS with IVS patients.

## Keywords

Heart Defects, Congenital, Pulmonary Valve Insufficiency, Tricuspid Valve Insufficiency, Case Report

## 1. Introduction

Absent pulmonary valve syndrome (APVS) is an uncommon congenital heart defect usually associated with tetralogy of Fallot (TOF). APVS can present as an “isolated APVS” without TOF, characterized by biventricular physiology with a normal tricuspid valve annulus and either a normal or dilated right ventricle. Additionally, single-ventricle physiology condition is correlated with an underlying presence of tricus-

pid atresia or stenosis, along with right ventricular hypoplasia. [1, 2] APVS with an intact ventricular septum (IVS) or a small ventricular septum are rare subtypes of APVS and are associated with a high perinatal mortality. [3] Based on data from the foetal echocardiography database, the average gestational age for diagnosis can be as early as 21.5 weeks of gestation. [1] Out of the APVS cases, APVS with IVS accounts for only

\*Corresponding author: drshuhualuo@gmail.com (Shuhua Luo)

**Received:** 31 January 2024; **Accepted:** 21 February 2024; **Published:** 29 February 2024



Copyright: © The Author(s), 2024. Published by Science Publishing Group. This is an **Open Access** article, distributed under the terms of the Creative Commons Attribution 4.0 License (<http://creativecommons.org/licenses/by/4.0/>), which permits unrestricted use, distribution and reproduction in any medium, provided the original work is properly cited.

7.5% to 25%, yet previous studies show a heart transplantation-free survival rate of just 20%. [4] Patients with APVS with IVS typically have a patent ductus arteriosus (PDA), and a large PDA could lead to tracheobronchial compression. [5] The combination of tracheobronchial compression and right ventricle dilation postnatally can result in respiratory dysfunction, heart failure, and severe infections for patients. [6].

Moreover, approximately 35% of the patients whose fetuses were prenatally diagnosed with APVS on ultrasound imaging opted for a termination of pregnancy. [5] With the improvement of postnatal care and intervention, the survival rate of patients born with APVS has increased from 20% to 80% [7].

Nevertheless, the impact of timely surgical intervention on long-term survival in patients with APVS and IVS remains uncertain. Moreover, symptoms are known to differ depending on each individual case.

Therefore, we recounted a rare case of the subtype, APVS with IVS in a patient with a combination of congenital heart defects, including an absent superior vena cava and pulmonary valve leaflets, as well as an IVS. Furthermore, this novel case was reported on, because the patient had a surprisingly long-term survival and underwent a timely pulmonary valve implantation.

## 2. Case Presentation

A 27-year-old male patient was admitted to our hospital with palpitations, as well as resting and exertional dyspnoea for a period of approximately 8 months. Chest pain, cyanosis, and lower limb oedema were absent. On admission, his peripheral oxygen saturation was 100%. In addition, an arterial blood gas analysis revealed that the partial pressures of oxygen and carbon dioxide, total haemoglobin, and haematocrit were 89.4 mm Hg, 33.9 mm Hg, 131.4 g/L and 38.4%, respectively. Although he did not have a family history of cardiovascular disease, he was diagnosed with APVS with IVS and tricuspid regurgitation at the age of 18. Nonetheless, no medical or surgical intervention had been performed, as his symptoms had been mild.

Murmurs were heard in the second intercostal space to the left of the sternal border during auscultation, both during systole and diastole. The electrocardiogram indicated atrial fibrillation, partial right bundle branch block, right ventricular hypertrophy, and abnormal T-wave changes. The presence of a pulmonary embolism was excluded by computed tomographic angiography. Transthoracic echocardiography revealed an IVS and concordant atrioventricular and ventriculo-arterial connections. A PDA was not found in our patient. Considerable dilatations of the right atrium (RA) and RV were present (RA= 70 mm, RV= 39 mm, respectively). Furthermore, both ventricles showed a reduced systolic function, with a left ventricular ejection fraction (LVEF) of 54% and a tricuspid annular plane systolic excursion (TAPSE) of 14 mm (Figure 1a). During the colour flow mapping, the systole

frame revealed a severe tricuspid valve regurgitation (Figure 1b). A rudimentary pulmonary valve, with the pulmonary valve annulus diameter measuring 4 mm was observed, in addition to severe regurgitation at the orifice. The pulmonary branches were not dilated (Figure 1c). Colour and spectral Doppler imaging during diastole revealed to-and-fro blood flow across the dysplastic pulmonary valve, with a pressure gradient of 75 mm Hg and peak velocity of 432 cm/s (Figure 1d).

The patient underwent an open-heart artificial 23 mm Hancock II pulmonary valve implantation and 28 mm Edwards MC3 tricuspid ring (Model 4900; Edwards Lifesciences, Irvine, CA, USA) annuloplasty at our hospital. The intraoperative view showed considerable delimitation between the normal cardiac muscle and proliferative fibrous tissue (Figure 2). Because the pulmonary valve leaflets were absent, they were substituted with a restrictive ring of thickened tissue. Furthermore, the tricuspid valve annulus was dilated. Through open-heart surgery, the right ventricular systolic pressure was obtained through catheterization of the right ventricle, measuring 30 mm Hg.

The patient was successfully weaned off the cardiopulmonary bypass. And the transthoracic echocardiography confirmed no regurgitation of the tricuspid and pulmonary valves, both during the systolic (Figure 3a, c) and diastolic (Figure 3b, d) periods. He was discharged from the intensive care unit on the fourth day after the surgery, and then discharged home on the 22nd day after the surgery.

During the 3-month follow-up evaluation, the patient was assessed to be in good health. Transthoracic echocardiography showed a significant decrease in the right heart chamber dilatations (RA = 54 mm; RV = 20 mm). Systolic function of both ventricles improved, with an LVEF of 63% and TAPSE of 12 mm. Additionally, there was no observed regurgitation of the tricuspid and pulmonary valves.

## 3. Discussion

In this case, we reported on the rare subtype APVS with IVS to emphasise the importance of life-long follow-up for the potential indication of subsequent surgery in patients with this congenital heart defect. More importantly, the findings of our study highlighted the timeliness of a pulmonary valve implantation, which was formerly unknown, because none of the previous studies discussed below have reported on this timeliness, due to the rarity of this malformation.

Although the aetiology of APVS with IVS is unclear, ventricular dysfunction secondary to a large PDA has been assessed to be a predictor of mortality. [4] Volume overload due to a PDA is limited to the RV when the interventricular septum is intact. Additionally, severe regurgitant flow from the pulmonary valve might further impair RV development. Monacchi et al. and Favilli et al. have demonstrated that the spontaneous or surgical closure of the ductus arteriosus (DA), along with the progressive reduction in pulmonary vascular resistance,

are crucial factors in enhancing pulmonary forward flow and enhancing both systolic and diastolic right ventricular functions. [2, 5] Furthermore, the patient's haemodynamic and clinical conditions may improve even though the RV is dilated, due to good contractility. Immediate pulmonary valve surgery is unnecessary. Early ligation of the DA is important for treating this malformation. [8, 9] Thus, we hypothesised that the DA within our patient had spontaneously closed, and that successful biventricular circulation had been obtained when the patient was in the foetal stage, without the development of an impaired tricuspid valve. Nonetheless, if patients should fail to develop good ventricular contractility, however with secondary congestive heart failure, the Blalock–Taussig Shunt or a heart transplantation must be performed promptly, within a few days, postnatally. [4]

Despite a viable live birth, severe RV dysfunction can develop if the dilatation of the RV is sustained. Okajima et al. reported that a 60-year-old patient with APVS with IVS successfully survived for a long time; however, no surgical information was provided in their case. [10] Our patient developed severe valve regurgitation and heart dilatation at a younger age. Initially, pulmonary valve implantation was performed to prevent congestive heart failure. Postoperatively, RV function improved quickly, and the RV dilatation was reduced in a very short time. Although Matthew S. Yong et al. reported that long-term survival for APVS with TOF patients has improved during the last decade. [11, 12] The long-term survival of APVS with IVS patients was still blank.

## Appendix

## 4. Conclusion

Therefore, our study highlighted that biventricular circulation can be successfully achieved in a patient with a rare subtype of APVS with IVS, during the foetal stage. However, as in the case of our patient, lifelong follow-up is essential for patients with this congenital heart defect to determine the potential indication for and timeliness of a pulmonary valve implantation. More multi-centre studies are required to avoid over-dilatation of the right-side of the heart.

## Abbreviations

APVS with IVS: Absent Pulmonary Valve Syndrome with an Intact Ventricular Septum

APVS: Absent Pulmonary Valve Syndrome

TOF: Tetralogy Of Fallot

PDA: Patent Ductus Arteriosus

RV: Right Ventricle

RA: Right Atrium

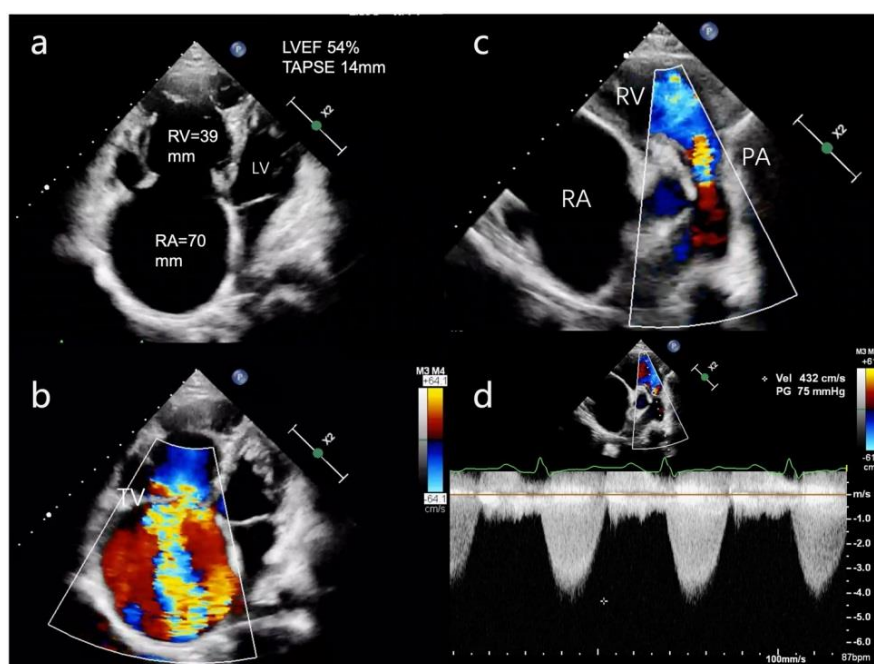
LVEF: Left Ventricular Ejection Fraction

TAPSE: Tricuspid Annular Plane Systolic Excursion

DA: Ductus Arteriosus

## Conflicts of Interests

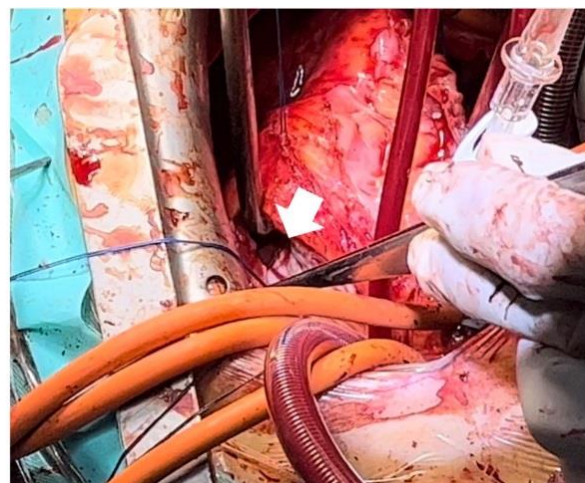
All authors declare that this manuscript has no conflict of interest.



**Figure 1.** Transthoracic echocardiography of the isolated absent pulmonary valve syndrome patient.

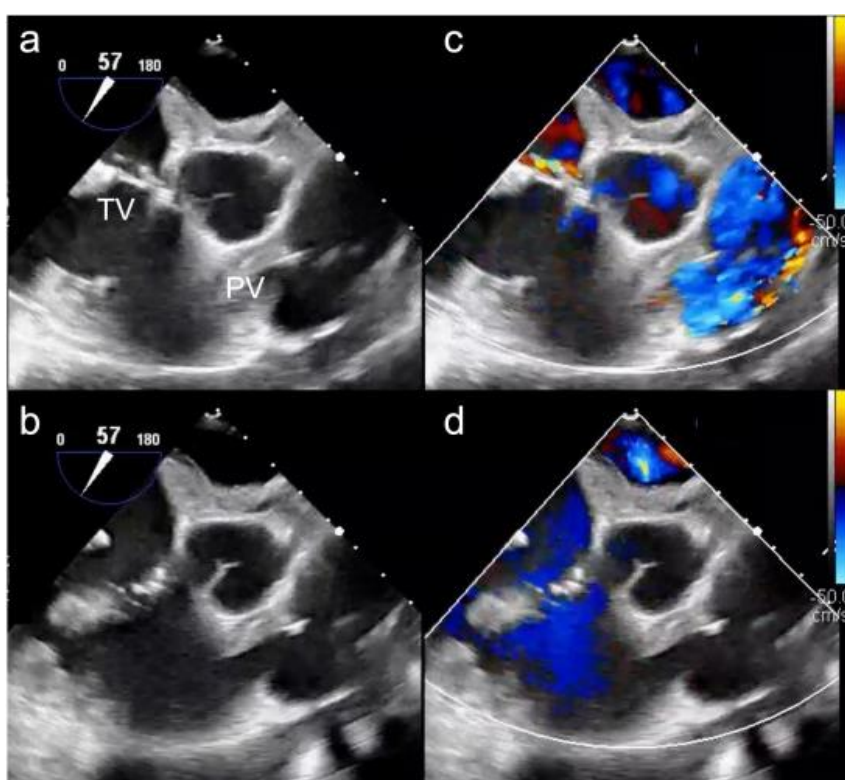
- The four-chamber view reveals an IVS, as well as concordant atrioventricular and ventriculo-arterial connections. Considerable dilations of the RA and RV are present (RA= 70 mm, RV= 39 mm, respectively). Furthermore, both ventricles show a reduced systolic function, with an LVEF of 54% and a TAPSE of 14 mm.
- During the colour flow mapping, the systole frame reveals severe tricuspid regurgitation.
- A rudimentary pulmonary valve, with the pulmonary valve annulus diameter measuring 4 mm is observed, in addition to severe regurgitation at the orifice during diastole, on the short axis view of the great arteries. Furthermore, the pulmonary branches are not dilated.
- Colour and spectral Doppler imaging during diastole reveal to-and-fro blood flow across the dysplastic pulmonary valve, with a PG of 75 mm Hg and PV of 432 cm/s.

LV: left ventricle; LVEF: left ventricular ejection fraction  
 IVS: intact ventricular septum; PA: pulmonary artery; PG: pressure gradient; PV: peak velocity; RA: right atrium; RV: right ventricle; TAPSE: tricuspid annular plane systolic excursion; TV: tricuspid valve.



**Figure 2.** Intraoperative view of the absent pulmonary valve leaflets.

The arrow marks the delimitation between the normal cardiac muscle and proliferative fibrous tissue, shown on the intraoperative view. This area represents the absent pulmonary valve leaflets, which has been substituted with a restrictive ring of thickened tissue.



**Figure 3.** Postoperative transesophageal echocardiography of the tricuspid valve and pulmonary valve.

This section of the right ventricular inflow and outflow tracts reveal no regurgitation of the tricuspid and pulmonary valves, both during the systolic (a) (c) and diastolic (b) (d) periods.

TV: tricuspid valve; PV: pulmonary valve

## References

- [1] Axt-Fliedner R, Kurkevych A, Slodki M, et al. Absent pulmonary valve syndrome - diagnosis, associations, and outcome in 71 prenatally diagnosed cases. *Prenat Diagn.* 2017; 37(8): 812-819. <https://doi.org/10.1002/pd.5094>
- [2] Monacci F, Bondi T, Canessa C, Chiappa E. 'Absent' pulmonary valve with intact ventricular septum mimicking tricuspid valve atresia: Prenatal diagnosis and postnatal course. *J Obstet Gynaecol Res.* 2019; 45(3): 714-718. <https://doi.org/10.1111/jog.13878>
- [3] Babaoğlu K, Doğan Y, Erdem S, Özbarlas N, Başar E, Uzun O. Prenatal Diagnosis, Associations and Outcome for Fetuses with Congenital Absence of the Pulmonary Valve Syndrome. *Anatol J Cardiol.* 2022; 26(9): 702-709. <https://doi.org/10.5152/AnatolJCardiol.2022.1461>
- [4] Szwast A, Tian Z, McCann M, et al. Anatomic variability and outcome in prenatally diagnosed absent pulmonary valve syndrome. *Ann Thorac Surg.* 2014; 98(1): 152-158. <https://doi.org/10.1016/j.athoracsur.2014.03.002>
- [5] Favilli S, Lapi E, Pollini I, Calabri GB, Bini RM. Prenatal diagnosis and postnatal outcome in patients with absent pulmonary valve syndrome not associated with tetralogy of Fallot: report of one case and review of the literature. *J Cardiovasc Med (Hagerstown).* 2008; 9(11): 1127-1129. <https://doi.org/10.2459/JCM.0b013e3283100eb1>
- [6] Recker F, Weber EC, Strizek B, Geipel A, Berg C, Gembruch U. Management and outcome of prenatal absent pulmonary valve syndrome. *Arch Gynecol Obstet.* 2022; 306(5): 1449-1454. <https://doi.org/10.1007/s00404-022-06397-4>
- [7] Wertaschnigg D, Jaeggi M, Chitayat D, et al. Prenatal diagnosis and outcome of absent pulmonary valve syndrome: contemporary single-center experience and review of the literature. *Ultrasound Obstet Gynecol.* 2013; 41(2): 162-167. <https://doi.org/10.1002/uog.11193>
- [8] Avdikos V, Johansson Ramgren J, Hans áus K, Malm T, Liuba P. Outcomes following surgical repair of absent pulmonary valve syndrome: 30 years of experience from a Swedish tertiary referral centre. *Interact Cardiovasc Thorac Surg.* 2022; 35(2): ivac193. <https://doi.org/10.1093/icvts/ivac193>
- [9] Rakha S, Alkhushi N. Fetal diagnosis of isolated absent pulmonary valve with intact interventricular septum: How to counsel the parents?. *Ann Pediatr Cardiol.* 2020; 13(2): 136-140. [https://doi.org/10.4103/apc.APC\\_101\\_19](https://doi.org/10.4103/apc.APC_101_19)
- [10] Okajima K, Kawase Y, Hasegawa T, et al. Long-surviving patient with isolated absent pulmonary valve syndrome: A case report. *Journal of Cardiology.* 2005; 45(4): 165-171. PMID: 15875539.
- [11] Yong MS, Yim D, Brizard CP, et al. Long-term outcomes of patients with absent pulmonary valve syndrome: 38 years of experience. *Ann Thorac Surg.* 2014; 97(5): 1671-1677. <https://doi.org/10.1016/j.athoracsur.2014.01.035>
- [12] Torok K, Brettle E, Desai T, et al. Long-term outcomes in children with absent pulmonary valve syndrome: it is not just fixing the heart. *Arch Dis Child.* 2021; 106(9): 877-881. <https://doi.org/10.1136/archdischild-2020-320219>