

Case Report

## Eruptive Xanthomas – A Case Report with a Review of the Literature

**Balkis El Darawish<sup>1</sup>** , **Valentina Broshtilova<sup>2</sup>** , **Irina Yungareva<sup>3</sup>** ,  
**Nencho Smilov<sup>4</sup>** , **Aleksandar Trenovski<sup>5</sup>** , **Yoanna Velevska<sup>6</sup>** ,  
**Sonya Marina<sup>3,\*</sup>** 

<sup>1</sup>Spectro - Institute of Medical Aesthetics, Sofia, Bulgaria

<sup>2</sup>Department of Internal Medicine, Pharmacology and Clinical Pharmacology, Pediatrics, Epidemiology, Infectious Diseases and Dermatology, Faculty of Medicine, Sofia University, Sofia, Bulgaria

<sup>3</sup>Department of Skin and Venereal Diseases, Medical Institute of the Ministry of Internal Affairs, Sofia, Bulgaria

<sup>4</sup>Clinic of Urology, Medical Institute of the Ministry of Internal Affairs, Sofia, Bulgaria

<sup>5</sup>Department of Anesthesiology and Intensive Care, Medical Institute of the Ministry of Internal Affairs, Sofia, Bulgaria

<sup>6</sup>Department of Infectious Diseases, Parasitology and Dermatovenereology, Medical University, Varna, Bulgaria

### Abstract

Eruptive xanthomas are most often the result of impaired lipid metabolism. They can be caused by a primary dysregulation in lipid metabolism (familial hyperlipoproteinemias) or by an increase in serum lipids from concomitant diseases (diabetes mellitus, obesity, chronic renal failure, nephrotic syndrome, pancreatitis, hypothyroidism, rarely hyperthyroidism, alcohol abuse, cholestasis or biliary cirrhosis, monoclonal gammopathy, multiple myeloma and leukemia) or from the use of certain medications (beta-blockers, estrogens, retinoids, protease inhibitors, cyclosporine, the antimycotic Miconazole and the antipsychotic Olanzapine (secondary hyperlipoproteinemias). Early diagnosis and adequate therapy of the skin changes and the comorbid underlying disease prevent serious life-threatening complications. A case of a 34-year-old man with papular yellowish lesions on the elbows is presented. The patient has accompanying diseases of diabetes mellitus, alcohol addiction, liver cirrhosis, chronic acute pancreatitis and chronic cholecystitis. The clinical diagnosis of eruptive xanthomas was confirmed by histopathological examination revealing foam cells in the dermis. Laboratory blood tests revealed an accelerated ESR and elevated blood glucose, transaminases, uric acid, total cholesterol, and triglycerides. Hepatoprotective and antidiabetic therapy combined with a dietary regimen improved the patient's condition and laboratory parameters. A partial reversal of skin lesions occurred. An overview of the epidemiology, etiopathogenesis, clinical picture, laboratory tests, differential diagnosis, dietary regimen, and treatment of eruptive xanthomas are presented.

### Keywords

Eruptive Xanthomas, Chronic Alcohol Abuse, Dyslipidemia

\*Corresponding author: [soniamarina1@yahoo.com](mailto:soniamarina1@yahoo.com) (Sonya Marina)

**Received:** 15 April 2024; **Accepted:** 10 May 2024; **Published:** 30 May 2024



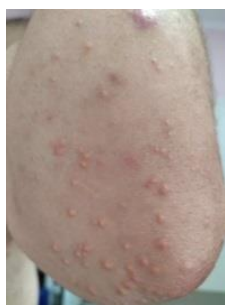Copyright: © The Author(s), 2024. Published by Science Publishing Group. This is an **Open Access** article, distributed under the terms of the Creative Commons Attribution 4.0 License (<http://creativecommons.org/licenses/by/4.0/>), which permits unrestricted use, distribution and reproduction in any medium, provided the original work is properly cited.

## 1. Introduction

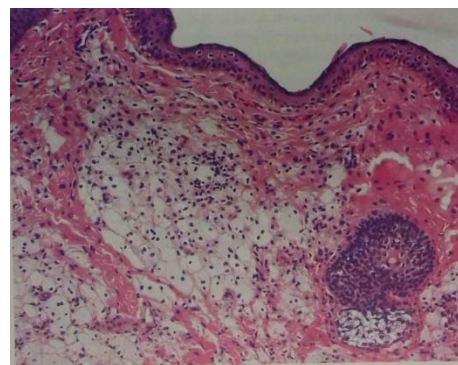
Skin manifestations often indicate underlying systemic dysfunctions that can potentially lead to life-threatening complications [1-3]. Xanthomas, first described in the early twentieth century, are rare benign neoplasms associated with disturbances in lipid metabolism [4]. They can manifest as a dermatological indication of metabolic diseases, generalized histiocytosis, or localized lipid phagocytosis. Eruptive xanthomas (EX) typically occur in the setting of extreme hypertriglyceridemia linked with underlying lipid metabolic disorders [5-11]. While hereditary cases are commonly associated with primary hyperlipoproteinemias [12], instances with normal serum lipid levels have also been documented [11, 13].

## 2. Clinical Case

A 34-year-old man presented with a sudden onset of mildly pruritic, multiple, clustered, yellowish, firm, raised skin papules on the elbows (Figure 1). He reported consuming a significant amount of alcohol systemically (approximately 750 ml of concentrate daily) for at least one year. There was a positive family history of hereditary hyperlipidemia and diabetes mellitus. The patient was obese, with a body mass index of 38 kg/m<sup>2</sup> and had arterial hypertension (average blood pressure 150/95 mmHg). Laboratory findings revealed elevated hyperglycemia, liver function tests indicating hepatocellular damage (AST 62 IU/L, ALT 223 IU/L, GGT 108 IU/L), increased acute inflammatory markers (ESR 80 mm/h), and dyslipidemia (total cholesterol 8.9 mmol/L, triglycerides 6.34 mmol/L). Histological examination demonstrated compact conglomerates of lipid-laden macrophages with foamy and vacuolated cytoplasm in the dermis (Figure 2), consistent with eruptive xanthomas. Abdominal ultrasound revealed hepatosplenomegaly, nephrolithiasis in the left kidney, chronic pancreatitis, and cholecystitis. The patient underwent systemic antidiabetic therapy with metformin and hepatoprotective therapy with ademetonine. A strict low-fat and low-carbohydrate diet was advised, and alcohol use was discontinued. At the 2-month follow-up, there was partial resolution of skin lesions with a decrease in blood sugar to 5.5 mmol/L, total cholesterol to 5.2 mmol/L, and triglycerides to 1.4 mmol/L.



**Figure 1.** Multiple miliar to lenticular firm yellowish papules on the left elbow.



**Figure 2.** H&E, x 40 Histological examination demonstrated lipid-laden macrophages with foamy and vacuolated cytoplasm, forming compact conglomerates in the dermis.

## 3. Discussion

Approximately 8.5% of individuals with severe hypertriglyceridemia develop xanthomas during their lifetime [8]. Patients with familial hypercholesterolemia typically develop eruptive xanthomas in their second or third decade [14]. There is no sex predisposition. Xanthomas result from disturbances in lipid metabolism and local dysfunction of tissue macrophages, which often exhibit reduced lipoprotein lipase activity. Consequently, elevated serum lipids cannot be effectively metabolized, leading to their accumulation within cells. Eruptive xanthomas can arise in both hyperlipidemic and normolipidemic patients, although primary (familial) dyslipidemias caused by genetically determined defects in lipid metabolism are more commonly observed [12, 15-17].

The pathogenetic mechanisms underlying eruptive xanthomas are not fully understood, but it is hypothesized that their occurrence parallels the formation of atherosclerotic vascular changes [16]. Mechanical injury to the vascular wall increases the permeability of dermal capillaries, allowing pathological lipoproteins to exit the vascular bed and accumulate in macrophages, giving rise to characteristic "foamy" cytoplasmic cells and, less frequently, multinucleated Touton giant cells. The mechanisms driving normolipidemic xanthomatosis remain unclear [13]. The secondary disorder of lipid metabolism in the presented patient is the result of obesity, diabetes mellitus, damage to the liver and pancreas, and systemic alcohol abuse.

Fredrickson-Levy and Lee classified familial lipoproteinemias into six distinct classes, with eruptive xanthomas most commonly associated with elevated levels of chylomicrons and VLDL (types I, IV, and V) [12, 18, 19]. The condition is also part of the "chylomicronemia" syndrome, characterized by serum chylomicron levels exceeding 1000 mg/dl, lipemia retinalis, and gastrointestinal symptoms [20-22]. Eruptive xanthomas can also develop in secondary hyperlipoproteinemias secondary to conditions such as diabetes mellitus, obesity, chronic renal failure, nephrotic syndrome, pancreatitis, hypothyroidism, rarely hyperthyroidism, alcoholism, cholestasis or biliary cirrhosis, monoclonal gammo-

pathy, multiple myeloma, and leukemia [12, 18, 23-29]. Notably, eruptive xanthomas are more prevalent in patients with type 2 diabetes [30]. Psycho-emotional stress, pregnancy, and certain medications (beta-blockers, estrogens, retinoids, protease inhibitors, cyclosporine, antimycotic, and antipsychotic drugs) can also induce hyperlipoproteinemia or hypertriglyceridemia, leading to eruptive xanthoma manifestations [31-34]. Paraproteinemia and lymphoproliferative diseases such as histiocytosis or myeloma may manifest or develop eruptive xanthomas during their course [35-38].

Eruptive xanthomas are characterized by a sudden onset of milia-like and lenticular papules, sometimes with a small erythematous halo. They typically measure 1-4 mm in diameter, occasionally larger. Lesions resembling vesicles or pseudo-pustules have also been reported [39]. Papules may be discrete, disseminated, clustered, or confluent in plaques. Their coloration varies from erythematous, erythematous-yellowish, yellowish-brown, orange-yellowish to yellowish. Predilection sites include the extensor surfaces of the limbs, shoulder girdle, gluteal region, thighs, and areas above pressure points, with elbows and knees being predominantly affected. Involvement of facial skin and oral mucosa is rare [18, 40]. Isolated cases of eruptive xanthomas exhibiting the Köbner phenomenon have been described [35, 41, 42]. The lesions are typically asymptomatic, occasionally tender, and rarely pruritic.

Histologically, eruptive xanthomas feature abundant foamy histiocytes laden with lipid material, single Touton giant cells, and extracellular lipids in the dermis. An inflammatory infiltrate composed of lymphocytes, histiocytes, and neutrophils is often present [4, 43, 44].

Eruptive xanthomas pose a challenging differential diagnosis. Xanthoma disseminatum is a rare disease of unknown pathogenesis characterized by histiocytic proliferation as the primary feature, with lipid deposits occurring secondarily. It presents with numerous small reddish-brown papules distributed evenly on the face, skin folds, trunk, and proximal limbs [44, 45]. Disseminated granuloma annulare differs from eruptive xanthomas by the absence of perivascular and xanthomized histiocytes, lipid deposits, and hyaluronic acid deposition at the lesion margins [46, 47]. Non-Langerhans cell histiocytosis (micronodular form of juvenile xanthogranuloma) primarily affects children and young adults, typically presenting as a single orange-yellowish nodule localized on the scalp, face, or upper torso [48, 49]. Generalized eruptive histiocytosis (Langerhans cell histiocytosis) is a rare, benign, usually self-limiting disease characterized by the sudden onset of multiple, symmetrical, firm, erythematous, or brownish papules and nodules on the face, trunk, and proximal extremities. Histopathological examination reveals numerous histiocytic cells with pale cytoplasm and an irregular reniform nucleus, without clear cells or Touton giant cells [50]. Chronic tophaceous gout presents with pale yellowish papules, nodules, or nodules on the ears, tendons, and bursae. Initially soft and sometimes fluctuant, the tophi gradually

thicken and harden. Inflammatory episodes may cause softening and fistula formation, with discharge of a mushy substance. Histopathological examination shows a foreign body-type granuloma with central urate crystals surrounded by histiocytes and foreign-body-type giant cells, with fibrous capsule formation during chronicity [51]. Pseudoxanthoma elasticum is a rare autosomal recessive disorder characterized by the deposition of calcium and other minerals mainly in elastic fibers of the skin, eyes, and blood vessels, less frequently in other tissues such as the digestive tract. Yellowish papules typically appear laterally on the neck, in the axillae, inguinal and flexural folds of the elbows and knees during the second or third decade of life. Common manifestations include visual impairment, periodic lower limb weakness, and gastrointestinal bleeding, particularly from the stomach [52]. Lipoid proteinosis, also known as Urbach-Wiethe syndrome or hyalinosis of the skin and mucosa, is an extremely rare autosomal recessive disorder characterized by lipid-protein deposits in various organs and tissues, including the skin and mucous membranes lining the oral cavity, larynx, vocal cords, respiratory tract, and eyes. Skin and mucous membranes thicken, with characteristic pearly papules on the eyelids. Skin becomes prone to injury, with bullae and cicatrix formation, nodular, warty, cobblestone-like lesions, and white or yellow infiltrates on the lips, buccal mucosa, tonsils, uvula, epiglottis, and frenulum of the tongue. Macroglossia may develop, alongside voice changes due to vocal cord thickening. Respiratory symptoms such as dyspnea and dry cough may occur, along with intracranial calcifications leading to epilepsy and neuropsychiatric abnormalities. Hair loss, mumps, dental abnormalities, corneal ulceration, and focal macular degeneration are rare. Histological examination typically reveals a thickened dermis with bundles of amorphous homogeneous hyaline-like substance in its upper layers [53, 54]. Molluscum contagiosum, caused by a virus of the Poxviridae family, presents with round, oval, or hemispherical papules and nodules with central umbilication [55]. Lesions may be skin-colored or pink-red, with larger mollusca exhibiting a central keratotic plug. They may appear singly, scattered, or in confluent mosaic patterns on the skin or mucous membranes. Histopathological examination reveals characteristic intracytoplasmic inclusion bodies (molluscum bodies). Acneiform drug reactions are associated with a history of medication use, with lesions regressing upon discontinuation [6].

In patients with eruptive xanthomas, evaluation should encompass the "Four Ds" - Diet, Drugs, Disorders of metabolism, and Diseases - associated with secondary hypertriglyceridemia [56-58]. Early diagnosis and treatment of underlying causative diseases (such as diabetes, chronic renal failure, pancreatitis, etc.) are crucial to prevent complications [9-11, 59, 60]. Spontaneous resolution of smaller xanthomas has been reported following liver transplantation and plasmapheresis [11, 14]. Management strategies include dietary modifications, weight reduction, and increased physical activity [5, 9, 11, 12, 18, 28]. A balanced low-calorie, low-fat

diet is essential to control blood sugar and triglyceride levels, with an emphasis on increased consumption of vegetables, salads, cereals, and fish, and decreased intake of saturated fats (found in meat, dairy products, coconut and palm oil) and sugars (found in carbonated drinks, biscuits, and sweets). Weight loss is achieved through a combination of diet and regular physical activity. If lesions persist, medications regulating lipid metabolism may be prescribed [7, 11, 14, 16, 18, 21, 56-58], including HMG-CoA reductase inhibitors (statins), fibrates (clofibrate, fenofibrate, etc.), cholesterol absorption inhibitors (ezetimibe), nicotinic acid (niacin), anion exchange resins (cholestyramine), and food supplements containing omega-3-unsaturated fatty acids. In cases where medical therapy is ineffective, local chemical destruction with trichloroacetic acid, cryotherapy, laser therapy, or surgical excision may be considered [11, 15, 20].

Adverse reactions to eruptive xanthoma treatment typically relate to systemic therapy. The use of HMG-CoA reductase inhibitors [Hydroxymethylglutaryl-CoA reductase inhibitors (statins)] is associated with well-known side effects ranging from mild myalgia to rare but severe complications such as rhabdomyolysis and necrotizing autoimmune myopathy [61].

## 4. Conclusions

Eruptive xanthomas (EX) represent a dermatological manifestation of underlying systemic dysfunctions, primarily disturbances in lipid metabolism. They can occur in both hyperlipidemic and normolipidemic individuals, with primary dyslipidemias being more common, particularly in familial cases. The pathogenesis of EX involves the accumulation of pathological lipoproteins within tissue macrophages, leading to characteristic skin lesions.

The diagnosis of EX requires careful evaluation and differentiation from other dermatological conditions presenting with similar manifestations, such as xanthoma disseminatum, disseminated granuloma annulare, non-Langerhans cell histiocytosis, generalized eruptive histiocytosis, chronic tophaceous gout, pseudoxanthoma elasticum, lipid proteinosis, molluscum contagiosum, and acneiform drug reactions.

Management of eruptive xanthomas involves addressing underlying systemic conditions contributing to hypertriglyceridemia, such as diabetes mellitus, chronic renal failure, and pancreatitis. Lifestyle modifications, including dietary changes, weight reduction, and increased physical activity, are essential components of therapy. Pharmacological interventions targeting lipid metabolism, such as HMG-CoA reductase inhibitors, fibrates, and cholesterol absorption inhibitors, may be prescribed if conservative measures are insufficient. In refractory cases, local interventions such as chemical destruction, cryotherapy, laser therapy, or surgical excision may be considered.

Adverse reactions to treatment, particularly systemic therapy with HMG CoA reductase inhibitors, should be monitored closely. Despite challenges, early diagnosis and comprehensive

management of eruptive xanthomas are crucial to prevent complications and improve patient outcomes. Further research is warranted to elucidate the pathogenetic mechanisms underlying this condition and to optimize therapeutic strategies.

## Abbreviations

AST	Aspartate Aminotransferase
ALT	Alanine Aminotransferase
GGT	GLUTAMYLTRANSFERASE
HMG-CoA	$\beta$ -Hydroxy $\beta$ -methylglutaryl-CoA

## Conflicts of Interest

The authors declare no conflicts of interest.

## References

- [1] Ahn CS, Yosipovitch G, Huang WW. Diabetes and the skin. In: Callen JP, Jorizzo JL, Zone JJ, Piette WW, Rosenbach MA, Vleugels RA, eds. *Dermatological Signs of Systemic Disease*. 5th ed. Philadelphia, PA: Elsevier; 2017: chap 24.
- [2] Braunstein I. Cutaneous manifestations of lipid disorders. In: Callen JP, Jorizzo JL, Zone JJ, Piette WW, Rosenbach MA, Vleugels RA, eds. *Dermatological Signs of Systemic Disease*. 5th ed. Philadelphia, PA: Elsevier; 2017: chap 26.
- [3] Fitzpatrick JE, High WA, Kyle WL. Yellow lesions. In: Fitzpatrick JE, High WA, Kyle WL, eds. *Urgent Care Dermatology: Symptom-Based Diagnosis*. Philadelphia, PA: Elsevier; 2018: chap 33.
- [4] McFarland J, McConnell G. Histologic studies of Xanthoma. *J Med Res*. 1904 Jul; 12(1): 69-74.
- [5] Brunzell JD. Clinical practice. Hypertriglyceridemia. *N Engl J Med* 2007; 357.10: 1009-1017.
- [6] Zaremba J, Zaczekiewicz A, Placek W. Eruptive xanthomas. *Postepy Dermatol Alergol* 2013; 30: 399-402.
- [7] Hegele RA, Ginsberg HN, Chapman MJ, et al. The polygenic nature of hypertriglyceridaemia: implications for definition, diagnosis, and management. *Lancet Diabetes Endocrinol*. 2014; 2: 655-666. [https://doi.org/10.1016/S2213-8587\(13\)70191-8](https://doi.org/10.1016/S2213-8587(13)70191-8)
- [8] Roga G, Jithendriya M. Eruptive xanthoma: Warning sign of systemic disease. *Cleve Clin J Med*. 2016; 83(10): 715-716. <https://doi.org/10.3949/ccjm.83a.15126>
- [9] Marogi EP, Ohimoba RO, Stone NJ. Eruptive Xanthomas: Importance of recognition to Reduce Delay of Effective Triglyceride Reduction. *Am J Med*. 2022; 135(4): 444-447. <https://doi.org/10.1016/j.amjmed.2021.09.026>
- [10] Rigolon de Lara J, Momente Miquelin G, Lapins J, et al. Eruptive Xanthoma as a Sign of Underlying Severe Metabolic Disorder. *Dermatol Pract Concept*. 2023; 13(1): e2023025. <https://doi.org/10.5826/dpc.1301a25>



- [11] Bell A, Shreenath AP. Xanthoma. StatPearls [Internet]. Last Update: August 28, 2023.
- [12] Parker F. Xanthomas and hyperlipidemias. *J Am Acad Dermatol*. 1985; 13(1): 1-30. [https://doi.org/10.1016/s0190-9622\(85\)70139-9](https://doi.org/10.1016/s0190-9622(85)70139-9)
- [13] Caputo R, Monti M, Berti E, et al. Normolipemic eruptive cutaneous xanthomatosis. *Arch Dermatol*. 1986; 122(11): 1294-1297.
- [14] Wanat K., Noe Megan H. Cutaneous Xanthomas. UpToDate; 10 Nov. 2017.
- [15] Pouwels ED, Blom DJ, Firth JC, et al. Severe hypertriglyceridaemia as a result of familial chylomicronaemia: the Cape Town experience. *S Afr Med J*. 2008; 98(2): 105-108.
- [16] Ison HE, Clarke SL, Knowles JW. Familial Hypercholesterolemia. In: Adam MP, Feldman J, Mirzaa GM, Pagon RA, Wallace SE, Bean LJH, Gripp KW, Amemiya A, editors. *GeneReviews*® [Internet]. University of Washington, Seattle; Seattle (WA): Jan 2, 2014.
- [17] Mabuchi H. Half a Century Tales of Familial Hypercholesterolemia (FH) in Japan. *J Atheroscler Thromb*. 2017; 24(3): 189-207. <https://doi.org/10.5551/jat.RV16008>
- [18] Roller E, Schulte KW, Hengge U, et al. Eruptive xanthomas. *Hautarzt*. 2004; 55(10): 978-980. <https://doi.org/10.1007/s00105-004-0810-8>
- [19] Quispe R, Hendrani AD, Baradaran-Noveiry B, et al. Characterization of lipoprotein profiles in patients with hypertriglyceridemic Fredrickson-Levy and Lees dyslipidemia phenotypes: the Very Large Database of Lipids Studies 6 and 7. *Arch Med Sci*. 2019; 15(5): 1195-1202. <https://doi.org/10.5114/aoms.2019.87207>
- [20] Brunzell JD, Bierman EL. Chylomicronemia syndrome. Interaction of genetic and acquired hypertriglyceridemia. *Med Clin North Am*. 1982; 66(2): 455-468.
- [21] Leaf DA. Chylomicronemia and the chylomicronemia syndrome: a practical approach to management. *Am J Med*. 2008; 69(2): 105-108.
- [22] Goldberg RB, Chait A. A Comprehensive Update on the Chylomicronemia Syndrome. *Front Endocrinol (Lausanne)*. 2020; 11: 593931. <https://doi.org/10.3389/fendo.2020.593931>
- [23] Archer CB, MacDonald DM. Eruptive xanthomata in type V hyperlipoproteinemia associated with diabetes mellitus. *Clin Exp Dermatol*. 1984; 9(3): 312-316.
- [24] Zadak Z. Internist's view on skin manifestations of hyperlipidemia in diabetic patients *Vnitr Lek*. 2006; 52(5): 465-469.
- [25] Zabeen B, Khaled Z, Nahar J, et al. Hypertriglyceridemia associated with eruptive xanthomas and lipemia retinalis in newly diagnosed diabetes mellitus. *Mymensingh Med J*. 2013; 22(3): 591-595.
- [26] Inoue-Nishimoto T, Hanafusa T, Hirohata A et al. Eruptive Xanthoma with Acute Pancreatitis in a Patient with Hypertriglyceridemia and Diabetes. *Ann Dermatol*. 2016; 28(1): 136-137. <https://doi.org/10.5021/ad.2016.28.1.136>
- [27] Suzuki L, Hirayama S, Fukui M, et al. Lipoprotein-X in cholestatic patients causes xanthomas and promotes foam cell formation in human macrophages. *J Clin Lipidol*. 2017; 11(1): 110-118.
- [28] Lee SY, Sheth CA. Eruptive xanthoma associated with severe hypertriglyceridemia and poorly controlled type 1 diabetes mellitus. *J Community Hosp Intern Med Perspect*. 2019; 9(4): 344-346. <https://doi.org/10.1080/20009666.2019.1650591>
- [29] Harris J, Cao S, Hile G, et al. Diffuse xanthomas in a patient with primary biliary cholangitis and lipoprotein X. *JAAD Case Rep*. 2020; 7: 30-32. <https://doi.org/10.1016/j.jdc.2020.10.029>
- [30] Ladizinski B, Lee KC. Eruptive xanthomas in a patient with severe hypertriglyceridemia and type 2 diabetes. *CMAJ*. 2013; 185: 1600.
- [31] Jaber PW, Wilson B, Johns D, et al. Eruptive xanthomas during pregnancy. *J Am Acad Dermatol*. 1992; 27(2Pt2): 300-302.
- [32] Dicken CH, Connolly SM. Eruptive xanthomas associated with isotretinoin (13-cis-retinoic acid). *Arch Dermatol*. 1980; 116(8): 951-952.
- [33] Barr RJ, Fujita WH, Graham JH. Eruptive xanthomas associated with intravenous miconazole therapy. *Arch Dermatol*. 1978; 114(10): 1544-1545.
- [34] Chang HY, Ridky TW, Kimball AB, et al. Eruptive xanthomas associated with olanzapine use. *Arch Dermatol*. 2003; 139(8): 1045-1048. <https://doi.org/10.1001/archderm.139.8.1045>
- [35] Roederer G, Xhignesse M, Davignon J. Eruptive and tubero-eruptive xanthomas of the skin arising on sites of prior injury. Two case reports. *JAMA*. 1988; 260(9): 1282-1283.
- [36] Eeckhout I, Vogelaers D, Geerts ML, et al. Xanthomas due to generalized oedema. *Br J Dermatol*. 1997; 136(4): 601-603.
- [37] Mai V, Akhondi H. Xanthomas: Differentiating atherogenic from nonatherogenic. *Cleveland Clinic J Med*. 2022; 89(8): 429-431. <https://doi.org/10.3949/ccjm.89a.21088>
- [38] Parker F. Normocholesterolemic xanthomatosis. *Arch Dermatol*. 1986; 122(11): 1253-1257.
- [39] Kashif M, Kumar H, Khaja M. An unusual presentation of eruptive xanthoma: A case report and literature review. *Medicine (Baltimore)*. 2016; 95(37): e4866. <https://doi.org/10.1097/MD.0000000000004866>
- [40] Song X, Zhang D, Zhao Z, et al. Multiple Red-brown Papules and Plaques on the Trunk and Extremities: A Quiz. *Acta Derm Venereol*. 2023; 103: adv12419. <https://doi.org/10.2340/actadv.v103.12419> PMID: 37721357
- [41] Brazzelli V, Rivetti N, Carugno A, et al. Eruptive xanthomas after extensive tattooing: a case report and literature review. *G Ital Dermatol Venereol*. 2015; 150(6): 770-1.

- [42] Gao H, Chen J. Eruptive xanthomas presenting in tattoos. *CMAJ*. 2015; 187(5): 356.  
<https://doi.org/10.1503/cmaj.140383>
- [43] Cruz PD, East C, Bergstresser PR. Dermal, subcutaneous, and tendon xanthomas: diagnostic markers for specific lipoprotein disorders. *J Am Acad Dermatol*. 1988; 19(1 Pt 1): 95-111.
- [44] Patterson JW. Cutaneous infiltrates - nonlymphoid. In: Patterson JW, ed. *Weedon's Skin Pathology*. 5th ed. Philadelphia, PA: Elsevier; 2021: chap 41.
- [45] Rupec RA, Schaller M. Xanthoma disseminatum. *Int J Dermatol* 2002; 41: 911-913.  
[https://doi.org/10.1046/j.1365-4362.2002.01680\\_1.x](https://doi.org/10.1046/j.1365-4362.2002.01680_1.x)
- [46] Cooper PH. Eruptive xanthoma: a microscopic simulant of granuloma annulare. *J Cutan Pathol* 1986; 13: 207-215.
- [47] Fagundes PP, Pinto AS, Pinto PA, et al. Eruptive xanthoma with unexpected granuloma annulare-like microscopic appearance: case report. *An Bras Dermatol*. 2009; 84(3): 289-292.  
<https://doi.org/10.1590/s0365-05962009000300013>
- [48] Hernandez-Martin A, Baselga E, Drolet BA, Esterly NB. Juvenile xanthogranuloma. *J Am Acad Dermatol*. 1997; 36(3 Pt 1): 355-359.
- [49] Dehner LP. Juvenile xanthogranulomas in the first two decades of life: a clinicopathologic study of 174 cases with cutaneous and extracutaneous manifestations. *Am J Surg Pathol*. 2003; 27(5): 579-593.  
<https://doi.org/10.1097/0000478-200305000-00003>
- [50] Wang J, Wu X, Xi ZJ. Langerhans cell histiocytosis of bone in children: a clinicopathologic study of 108 cases. *World J Pediatr*. 2010; 6: 255-259.  
<https://doi.org/10.1007/s12519-010-0205-0>
- [51] Bito T, Kawakami C, Shimajiri S, et al. Generalized eruptive xanthoma with prominent deposition of naked chylomicrons: evidence for chylomicrons as the origin of urate-like crystals. *J Cutan Pathol*. 2010; 37(11): 1161-1163.  
<https://doi.org/10.1111/j.1600-0560.2010.01558.x>
- [52] Jahr C, Vera V, Bustos R, et al. Diagnosis of pseudoxanthoma elasticum in a patient with discrete skin lesions. *An Bras Dermatol*. 2023; 98(4): 542-544.
- [53] Hamada T. Lipoid proteinosis. *Clin Exp Dermatol*. 2002 Nov; 27(8): 624-9.
- [54] Kim SM, Lee H, Kim YC. Eruptive Xanthoma With Dermal Mucin Deposition. *Am J Dermatopathol*. 2021; 43(8): 583-584.  
<https://doi.org/10.1097/DAD.0000000000001863>
- [55] Leung AKC, Barankin B, Hon KLE. Molluscum Contagiosum: An Update. *Recent Pat Inflamm Allergy Drug Discov*. 2017; 11(1): 22-31.  
<https://doi.org/10.2174/1872213X11666170518114456>
- [56] Yuan G, Al-Shali KZ, Hegele RA. Hypertriglyceridemia: its etiology, effects and treatment. *CMAJ*. 2007; 176(8): 1113-1120. <https://doi.org/10.1503/cmaj.060963>
- [57] Ranjan N. Management of hyperlipidemias: an update. *Indian J Dermatol Venereol Leprol*. 2009; 75(5): 452-462.  
<https://doi.org/10.4103/0378-6323.55387>
- [58] White LE, Horenstein MG, Shea CR. Xanthomas. In: Lebwohl MG, Heymann WR, Coulson IH, Murrell DF, eds. *Treatment of Skin Disease*. 6th ed. Philadelphia, PA: Elsevier; 2022: chap 256..
- [59] Nessel TA, Kerndt CC, Bills JA, et al. Eruptive xanthomas: a warning sign of future hyperlipidemia complications. *Int J Res Dermatol*. 2020; 6: 579-583.  
<https://doi.org/10.18203/issn.2455-4529>
- [60] Lind S, Olsson AG, Eriksson M, et al. Autosomal recessive hyper cholesterolaemia: normalization of plasma LDL cholesterol by ezetimibe in combination with statin treatment. *Intern Med*. 2004; 256(5): 406-412.  
<https://doi.org/10.1111/j.1365-2796.2004.01401.x>
- [61] Thompson PD, Panza G, Zaleski A, et al. Statin-Associated Side Effects. *J Am Coll Cardiol*. 2016; 67(20): 2395-2410.  
<https://doi.org/10.1016/j.jacc.2016.02.071>