

Research Article

Outcome of High Resolution Computed Tomography (HRCT) Scan of Chest of COVID-19 Affected Patients: A Study in a COVID-19 Dedicated Hospital

Marzuk Ahamed^{*}, Mohammad Ripon Sikder, Mohammad Mojibur Rahman, Sohel Rana Sumon, Mohammad Motiur Rahman, Abdur Rab Akanda, Mohammad Salehin Abedin

Department of Public Health and Life Science, University of South Asia, Dhaka, Bangladesh

Abstract

Introduction: Recent studies have assessed the importance of chest CT scans, particularly high-resolution CT (HRCT), in hospitalized COVID-19 patients who are suspected of having the virus or have had false negative test results. **Objective:** The aim of this study was to determine the outcome of High-Resolution Computed Tomography (HRCT) of chest of confirmed COVID-19 positive cases. **Methodology:** This was a cross-sectional prospective study carried out in the department of Radiology and imaging in collaboration with the department of Virology and COVID unit in IbnSina Hospital, Dhaka, Bangladesh during January, 2022 to June, 2022. A total of 300 confirmed COVID-19 positive admitted cases in the hospital, aged above 18 years were enrolled in this study. All the patients were under went High Resolution Computed Tomography (HRCT) of Chest scan. The collected data were cleaned, edited and entered into computer for analysis. The data were analyzed by SPSS-23.0. The ethical clearance of this study was obtained from the Ethics Committee of School of Public Health & Life Science, University of South Asia, and Dhaka, Bangladesh. **Results:** In this study a total of 300 COVID-19 positive cases were enrolled. Among the patients, the majority 203 (67.66%) patients belonged to the age group >52 years, which was the highest and followed by 44 (14.66%) age group (43-52) years, 36 (12%) (33-42) years, 14 (4.66%) (22-32) years and 3 (1%) <22 years. According to sex distribution, the majority cases 160 (53.33%) were male and 140 (46.66%) were female. According to the distribution of clinical presentation, the highest symptom was observed, general weakness 300 (100%) and followed by sneezing 288 (96%), fever 246 (82%), headache 239 (79.66%), cough 232 (77.33%), respiratory distress, 225 (75%), cough and SOB, 220 (73.33%), loss of smell, 222 (74%), lac of apatite, 216 (72%), asthma 130 (43.33) and pneumonia, 120 (40%). According to the distribution of HRCT findings of chest of the COVID-19 positive cases, 163 (54.33%) had Ground glass opacity, which was the largest observation and followed by 66 (22%), Ground glass opacity with pneumonia, 34 (11.33%) Ground glass opacity with consolidation, 31 (10.33) Ground glass opacity with fibrosis, and 6 (2%) Ground glass opacity with pleural effusion. **Conclusion:** The results of this study indicate that doing a high-resolution computed tomography (HRCT) scan of the chest is a valuable method for diagnosing and assessing the response to treatment in COVID-19 patients. Additionally, it serves as a significant predictor for future prognosis.

Keywords

Outcome. HRCT, Scan, Chest COVID-19, Positive, Cases, Ground Glass Opacity (GGO), Dedicated, Hospital

^{*}Corresponding author: marzukaha@gmail.com (Marzuk Ahamed)

Received: 1 November 2023; **Accepted:** 2 January 2024; **Published:** 24 May 2024



Copyright: © The Author(s), 2024. Published by Science Publishing Group. This is an **Open Access** article, distributed under the terms of the Creative Commons Attribution 4.0 License (<http://creativecommons.org/licenses/by/4.0/>), which permits unrestricted use, distribution and reproduction in any medium, provided the original work is properly cited.

1. Introduction

COVID-19 is a highly contagious illness caused by the SARS-CoV-2 virus. The World Health Organization (WHO) officially classified this pandemic as a worldwide health crisis in February 2020. The initial case was documented on March 8th, 2020 in Bangladesh, and the first fatality occurred on March 18th, 2020 [1-4]. RT-PCR of viral nucleic acid is considered the gold standard for diagnosing COVID-19. However, in cases when RT-PCR results are negative in symptomatic patients, HRCT scan of the chest is an essential diagnostic test and a viable alternative to RT-PCR [5]. Recent studies have assessed the importance of chest computed tomography (CT), particularly high-resolution CT (HRCT), in hospitalized COVID-19 patients who are suspected of having the virus or have had false negative test results [6]. According to some studies, a sensitivity of around 98% is crucial not only for diagnosing a condition but also for monitoring the progression of the disease and evaluating the effectiveness of treatment [7-9]. HRCT can assist in determining the temporal illness stage and severity of COVID Pneumonia. The SARS COV-2 PCR, which is the standard approach for diagnosing COVID-19, is quite accurate in identifying the virus although its ability to detect it can vary, with sensitivity levels as low as 70% [10]. Currently, in Bangladesh, around 30% of cases are asymptomatic or false negative, meaning they cannot be detected by RT-PCR due to a low viral load [11]. High-resolution computed tomography (HRCT) of the chest can have a crucial impact on the diagnosis of this patient. A chest CT scan can evaluate the advancement of a disease and provide information about its prognosis and potential outcome. Chest CT is a valuable tool for quickly assessing and prioritizing patients in various emergency rooms during the COVID-19 pandemic. Timely detection of COVID-19 is essential for the management and containment of the disease [12]. Compared to reverse transcription polymerase chain reaction (RT-PCR), high-resolution computed tomography (HRCT) of the chest imaging may serve as a dependable, convenient, and expeditious tool for diagnosing and evaluating COVID-19, caused by the coronavirus illness [13]. The characteristic feature of COVID-19 was the presence of ground glass opacities, either with or without consolidation, in the basal, peripheral, and posterior segments, distributed bilaterally. As the illness progresses, several intriguing novel CT findings have been reported, including the crazy paving pattern, vascular alterations, consolidation, and the reverse halo sign. The severity of CT results is reduced only when the observed findings consist only of ground glass hazes caused by interstitial edema. In mild instances, together with ground-glass opacities (GGO), the distribution is usually bilateral, peripheral, and mostly located in the subpleural and posterior regions. Furthermore, consolidation is noteworthy in this particular scenario. At this stage, non-cardiogenic pulmonary edema involves the accumulation of fluid in the in-

terstitial space of the lungs, which eventually leads to the accumulation of fluid in the alveoli. This can be observed by radiographic findings such as ground glass opacities, consolidation, and a pattern resembling crazy paving. Severe instances have pronounced ground glass opacities with a distinct crazy paving pattern, along with significant thickening of the septa that nearly fills the whole lung. Typically, multifocal widespread consolidation, pleural thickening with modest effusion, and traction bronchiectasis are seen. Additionally, the study identified some common observations, including the presence of enlarged lymph nodes in the mediastinum, numerous small nodules in the lungs, the appearance of tree-like structures in the bronchial tree, the occurrence of a collapsed lung, and the formation of cavities within the lung tissue [14]. Performing a prompt and precise evaluation of the severity of COVID-19 pneumonia using CT chest scans is both practical and might offer valuable assistance in making informed decisions regarding patient care. High Resolution computed tomography (HRCT) of the chest has quickly become a speedy and efficient diagnostic technique, providing a distinct and frequently unique presentation of COVID-19 pneumonia [15]. This research sought to assess the impact of hormone replacement therapy (HRT) on the chest in patients with COVID-19, in order to determine the severity of disease progression.

2. Objectives

2.1. General Objective

To determine the outcome of High-Resolution Computed Tomography (HRCT) of chest of confirmed COVID-19 positive cases.

2.2. Specific Objectives

- 1) To determine the clinical and demographic characteristics of COVID-19 positive cases.
- 2) To evaluate ground glass opacity in lung field of COVID-19 positive cases.
- 3) To find out CT signs of coronavirus pneumonia.

3. Methodology

This was a cross-sectional prospective study carried out in the department of Radiology and imaging in collaboration with the department of Virology and COVID unit in IbnSina Hospital, Dhaka, Bangladesh during January, 2022 to June, 2022. The purpose, benefits and risks of this study were disclosed to the participants/care givers in local language. Written informed consent was obtained from the study sub-

jects/care givers and a total of 300 confirmed COVID-19 positive admitted cases in the hospital, aged above 18 years were enrolled in this study. A purposive random sampling technique was used. All the patients were under went High Resolution Computed Tomography (HRCT) of Chest Examination. The data were collected through a pre-structured Case Record Form (CRF). The collected data were cleaned, edited and entered into computer for analysis. The data were analyzed using Statistical Package for Social Sciences (SPSS) software, version 23.0. Inferential statistical analysis were performed and the results were presented as frequency and percentage in tables and charts. The ethical clearance of this study was obtained from the Ethics Committee of School of Public Health & Life Science, University of South Asia, and Dhaka, Bangladesh. The formal permission was also taken from the director and registrar of IbnSina Hospital, Dhaka, Bangladesh. The inclusion and exclusion criteria of this study were as follows:

3.1. Inclusion Criteria

- 1) Confirmed COVID-19 Positive Cases by RT-PCR Test.
- 2) Agreed to do HRCT of chest.
- 3) Aged above 18 years

3.2. Exclusion Criteria

- 1) Non COVID-19 Cases
- 2) Disagreed to do HRCT of chest.
- 3) Aged < 18 years

4. Results

Table 1 shows the age distribution of the study subjects. 203 (67.66%) patients belonged to the age group >52 years, which was the highest and followed by 44 (14.66%) age group (43-52) years, 36 (12%) (33-42) years, 14 (4.66%) (22-32) years and 3 (1%) <22 years.

Table 1. Age distribution of the study subjects. (n=300).

Age in years	Frequency	Percentage
< 22	3	1
22-32	14	4.66
33-42	36	12
43-52	44	14.66
> 52	203	67.66
Total	300	100

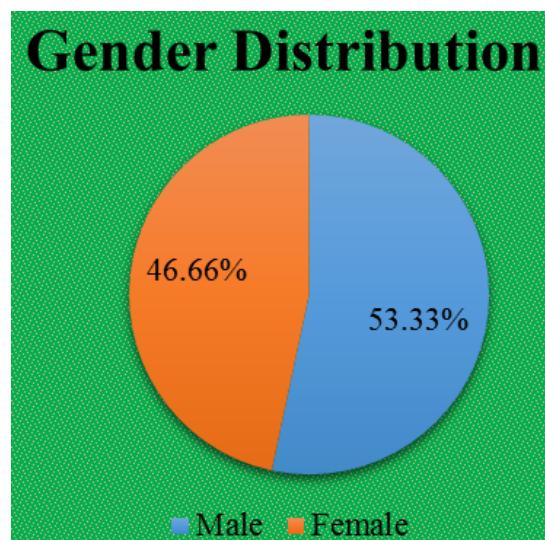


Figure 1. Shows the gender distribution of the study subjects (n=300).

Figure 1 shows the gender distribution of the study subjects. Among the COVID-19 positive cases 160 (53.33%) male and 140 (46.66%) were female.

Table 2 shows distribution of clinical presentation of the study subjects. Among the COVID-19 positive cases, the highest symptom was observed, general weakness 300 (100%) and followed by sneezing 288 (96%), fever 246 (82%), headache 239 (79.66%), cough 232 (77.33%), respiratory distress, 225 (75%), cough and SOB, 220 (73.33%), loss of smell, 222 (74%), lac of apatite, 216 (72%), asthma 130 (43.33) and pneumonia, 120 (40%).

Table 2. Distribution of clinical presentation of the study subjects. (n=300).

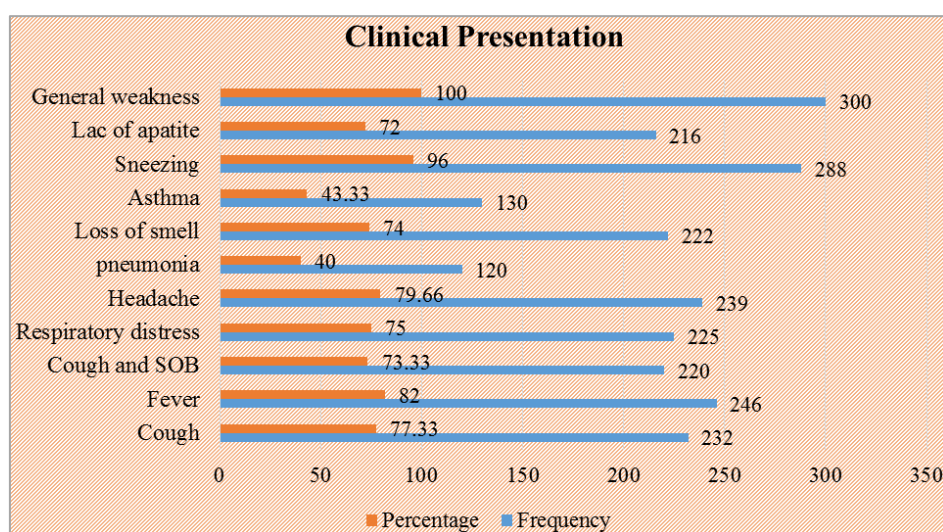
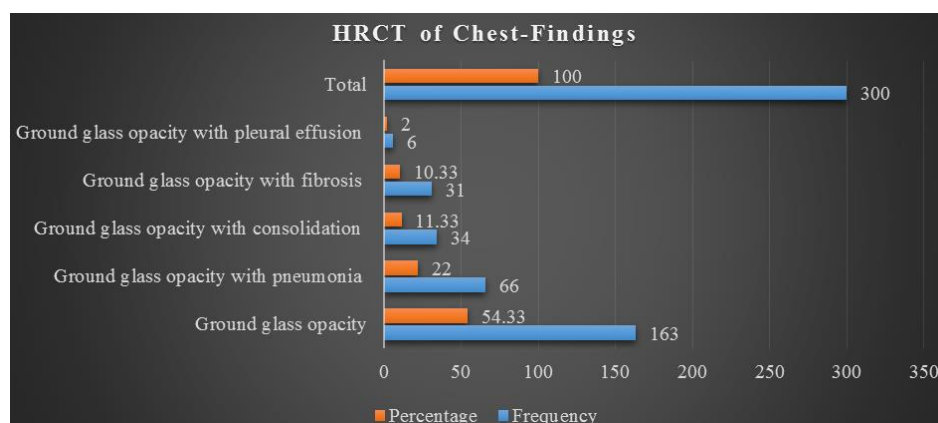
Clinical Presentation	Frequency	Percentage
Cough	232	77.33
Fever	246	82
Cough and SOB	220	73.33
Respiratory distress	225	75
Headache	239	79.66
pneumonia	120	40
Loss of smell	222	74
Asthma	130	43.33
Sneezing	288	96
Lac of apatite	216	72
General weakness	300	100

Table 3. Distribution of HRCT of Chest- Findings of the study subjects (n=300).

HRCT of Chest- Findings	Frequency	Percentage
Ground glass opacity	163	54.33
Ground glass opacity with pneumonia	66	22
Ground glass opacity with consolidation	34	11.33
Ground glass opacity with fibrosis	31	10.33
Ground glass opacity with pleural effusion	6	2

HRCT of Chest- Findings	Frequency	Percentage
Total	300	100

Table 3 shows the distribution of HRCT of chest- findings of the COVID-19 positive cases. Among the 300 patients, 163 (54.33%) had Ground glass opacity, which was the largest observation and followed by 66 (22%), Ground glass opacity with pneumonia, 34 (11.33%) Ground glass opacity with consolidation, 31 (10.33) Ground glass opacity with fibrosis, and 6 (2%) Ground glass opacity with pleural effusion.

**Figure 2.** Shows the clinical presentation of the study subjects (n=300).**Figure 3.** Shows the HRCT of Chest Findings of the study subjects (n=300).

5. Discussion

A positive RT-PCR test is necessary for a conclusive diagnosis of COVID-19. Current best practice recommends

against using HRCT scan of the chest for diagnosing COVID-19. However, it can be useful for evaluating complications, prognosis, and measuring the severity of the disease. Several authors have proposed that imaging should not be used in individuals with suspected COVID-19 and minor

clinical symptoms, unless they are at risk of disease progression. Imaging is recommended for a patient with COVID-19 who is experiencing deteriorating respiratory condition. Medical imaging is advised for the initial assessment of individuals displaying moderate to severe clinical symptoms and suspected to have COVID-19. HRCT symptoms can complement the limitations of real-time reverse transcription polymerase chain reaction (RT-PCR) test in diagnosis. Fifteen unless the machine is automated, the process is time-consuming. The HRCT scan is a good alternate diagnostic for diagnosing COVID pneumonia. The diagnostic accuracy of RT-PCR when using bronchoalveolar lavage is around 93%. The presence of the virus was detected in around 72% of sputum samples and around 63% of nasal swab samples. The number is 16. Bernheim et al. (2020) conducted a review of the computed tomography (CT) results of 121 symptomatic patients who were infected with COVID-19 [16]. The study focused on the timing of symptom onset and the initial CT scan. The findings indicate that patients who sought medical attention earlier had less ground-glass opacities (GGO) and consolidation compared to those who sought medical attention at an intermediate or late stage. Seventeen However, the illness severity in several cases did not align with the expected progression of the disease. Our study examines the HRCT findings of COVID-19, focusing on the extent to which the lung tissue is affected [17]. This analysis aims to understand the connection between HRCT findings and the severity of the illness. Out of the 300 patients, the most common observation was ground glass opacity, which was present in 163 individuals (54.33%). This was followed by ground glass opacity with pneumonia in 66 patients (22%), ground glass opacity with consolidation in 34 patients (11.33%), ground glass opacity with fibrosis in 31 patients (10.33%), and ground glass opacity with pleural effusion in 6 patients (2%). Comparable results were noted in many additional investigations published in the Journal of Radiology [18-20]. The research found that Chest HRCT had a high sensitivity for diagnosing COVID-19 in 1014 hospitalized patients with the condition. Chest HRCT can be regarded as a major diagnostic technique for detecting COVID-19 during an outbreak. Eighteen to twenty The primary imaging results consisted of bilateral distribution of ground glass opacities (GGO) and consolidation. The researchers discovered that chest CT yielded good results in 88% of the instances. Our analysis revealed the presence of ground glass opacities accompanied with consolidation. These opacities were distributed bilaterally, with a preponderance in the basal posterior and peripheral regions. 11 patients were found to have nodules. Twenty-two individuals had pleural effusion, whereas lymphadenopathy was seen in 14 patients. To accurately detect COVID-19, it is crucial to take into account a comprehensive analysis of clinical observations, imaging characteristics, and dynamic alterations, ensuring a heightened level of sensitivity. [21]. Recent research have shown that there is a substantial correlation between the severity of lung disease

and the extent of the illness as measured using a quantitative technique. In more severe instances, we noted a rise in the number of lung segments, the frequency of consolidation in the lobes, the presence of crazy paving, and the visibility of air bronchograms. Performing a prompt and precise evaluation of the severity of COVID-19 using chest CT scans is both achievable and can assist in making informed decisions on patient care. This approach has the potential to enhance the accuracy of diagnostic tests, with sensitivity and specificity exceeding 90% [22]. The range is from 22 to 25. Ultimately, this study proposes that all individuals who test positive for COVID-19 should get a high-resolution computed tomography (HRCT) scan of the chest in order to improve the prediction of outcomes and enhance the management of COVID-19 positive cases [23, 24].

6. Conclusion

This study examined the prevalence of different conditions in the study patients. Out of the total patients, the highest number (163 or 54.33%) had Ground glass opacity. Additionally, 66 patients (22%) had Ground glass opacity with pneumonia, 34 patients (11.33%) had Ground glass opacity with consolidation, 31 patients (10.33%) had Ground glass opacity with fibrosis, and 6 patients (2%) had Ground glass opacity with pleural effusion. The study's findings indicate that doing a high-resolution computed tomography (HRCT) scan of the chest is a valuable method for diagnosing and assessing the response to treatment in COVID-19 patients. Additionally, it serves as a significant predictor for the patient's future prognosis.

7. Limitations of the Study

This was a single center study with a limited purposive sample size and short study duration. So, the findings of this study may not reflect the whole country.

8. Recommendations of the Study

HRCT scan of chest is a useful modality for COVID-19 patients for the purpose of diagnosis and response to treatment. It is an important indicator for future prognosis. HRCT can be an important alternative of RT-PCR in symptomatic patients. It is important for the radiologists and clinicians to be familiar with different manifestations on HRCT. It will help in management planning for COVID-19 positive cases.

Ethical Approval

The ethical clearance of this study was obtained from the Ethics Committee of School of Public Health & Life Science, University of South Asia, and Dhaka, Bangladesh.

Conflicts of Interest

The authors declare no conflicts of interest.

References

- [1] Zhu N, Zhang D, Wang W, et al. A novel coronavirus from patients with pneumonia in China, 2019. *New Engl J Med* 2020; 382: 727-33. [PMC free article] [PubMed] [Google Scholar]
- [2] Wang C, Horby PW, Hayden FG, et al. A novel coronavirus outbreak of global health concern. *Lancet* 2020; 395: 470-3. [PMC free article] [PubMed] [Google Scholar]
- [3] Lu H, Stratton CW, Tang YW. Outbreak of pneumonia of unknown etiology in Wuhan China: the mystery and the miracle. *J Med Virol* 2020; 92: 401-2. [PMC free article] [PubMed] [Google Scholar]
- [4] Sohrabi C, Alsafi Z, O'Neill N, et al. World Health Organization declares global emergency: A review of the 2019 novel coronavirus (COVID-19). *Inter J Surg* 2020; 76: 71-6. [Google Scholar]
- [5] Kozera B, Rapacz M. Reference genes in real-time PCR. *J Appl Genet.* 2013 Nov; 54(4): 391-406. PMID: 24078518; PMCID: PMC3825189. <https://doi.org/10.1007/s13353-013-0173-x>
- [6] Ishfaq A, Farooq SM, Goraya A, Yousaf M, Gilani SA, Kiran A, Ayoub M, Javed A, Bacha R. Role of High Resolution Computed Tomography chest in the diagnosis and evaluation of COVID-19 patients-A systematic review and meta-analysis. *European journal of radiology open.* 2021 Jan 1; 8: 100350.
- [7] Ai T, Yang Z, Hou H, Zhan C, Chen C, Lv W, et al. Correlation of chest CT and RT-PCR testing for Coronavirus disease 2019 (COVID-19) in China: A report of 1014 cases. *Radiology* 2020; 296: E32-40.
- [8] Fang Y, Zhang H, Xie J, Lin M, Ying L, Pang P, et al. Sensitivity of chest CT for COVID-19: Comparison to RT-PCR. *Radiology* 2020; 296: E115-7.
- [9] Huang P, Liu T, Huang L, Liu H, Lei M, Xu W, et al. Use of chest CT in combination with negative RT-PCR assay for the 2019 novel coronavirus but high clinical suspicion. *Radiology* 2020; 295: 22-3.
- [10] Chen D, Jiang X, Hong Y, Wen Z, Wei S, Peng G, et al. Can chest CT features distinguish patients with negative from those with positive initial RT-PCR results for coronavirus disease (COVID-19)? *AJR Am J Roentgenol* 2020; 216: 66-70.
- [11] Raman S, Bahar T. COVID 19: The New Threat, *Int J Infect.* 2020; 7(1): e102184. <https://doi.org/10.5812/iji102184>
- [12] Bayraktaroğlu S, Çinkooğlu A, Ceylan N, Savaş R (2020) The novel coronavirus pneumonia (COVID-19): a pictorial review of chest CT features. *DiagnIntervRadiol.*
- [13] Kim H, Hong H, Yoon SH. Diagnostic performance of CT and reverse transcriptase polymerase chain reaction for coronavirus disease 2019: A meta- analysis. *Radiology* 2020; 296: E145-55.
- [14] Zhang, N., Xu, X., Zhou, L. et al. Clinical characteristics and Chest CT imaging features of critically ill COVID 19 patients. *EurRadiol* (2020).
- [15] Adams HJ, Kwee TC, Yakar D, Hope MD, Kwee RM. Systematic review and meta-analysis on the value of chest CT in the diagnosis of coronavirus disease (COVID-19): *Sol Scientiae, Illustra Nos. AJR Am J Roentgenol* 2020; 215: 1342-50.
- [16] Bernheim A, Mei X, Huang M, Yang Y, Fayad ZA, Zhang N, Diao K, Lin B, Zhu X, Li K, Li S, Shan H, Jacobi A, Chung M. Chest CT Findings in Coronavirus Disease-19 (COVID-19): Relationship to Duration of Infection. *Radiology.* 2020 Jun; 295(3): 200463. <https://doi.org/10.1148/radiol.2020200463>
- [17] Simpson S, Kay FU, Abbara S, Bhalla S, Chung JH, Chung M, et al. Radiological society of North America expert consensus document on reporting chest CT findings related to COVID-19: Endorsed by the society of thoracic radiology, the American College of Radiology, and RSNA. *J Thorac Imaging* 2020; 35: 219-27.
- [18] Paul NS, Roberts H, Butany J, Chung T, Gold W, Mehta S, Konen E, Rao A, Provost Y, Hong HH, Zelovitsky L, Weisbrod GL. Radiologic pattern of disease in patients with severe acute respiratory syndrome: the Toronto experience. *Radiographics* 2004; 24: 553-63. [Crossref] [PubMed]
- [19] Inui S, Fujikawa A, Jitsu M, Kunishima N, Watanabe S, Suzuki Y, Umeda S, Uwabe Y. Chest CT Findings in Cases from the Cruise Ship "Diamond Princess" with Coronavirus Disease 2019 (COVID-Radiology: Cardiothorac Imaging 2020. <https://doi.org/10.1148/ryct.2020200110>
- [20] Xu R, Du M, Li L, Zhen Z, Wang H, Hu X. CT imaging of one extended family cluster of corona virus disease 2019 (COVID-19) including adolescent patients and "silent infection". *Quant Imaging Med Surg* 2020; 10: 800-804. [Crossref] [PubMed]
- [21] Zhou Z, Guo D, Li C, Fang Z, Chen L, Yang R, Li X, Zeng W. Coronavirus disease 2019: initial chest CT findings. *Eur Radiol* 2020. Epub ahead of print. [Crossref] [PubMed]
- [22] Bai HX, Hsieh B, Xiong Z, Halsey K, Choi JW, Tran TML, Pan I, Shi LB, Wang DC, Mei J, Jiang XL, Zeng QH, Egglin TK, Hu PF, Agarwal S, Xie F, Li S, Healey T, Atalay MK, Liao WH. Performance of radiologists in differentiating COVID-19 from viral pneumonia on chest CT. *Radiology* 2020. Epub ahead of print. [Crossref] [PubMed]
- [23] Li Y, Xia L. Coronavirus disease 2019 (COVID-19): role of chest CT in diagnosis and management. *AJR Am J Roentgenol* 2020. Epub ahead of print. [Crossref] [PubMed]
- [24] Ng MY, Lee M, Yang J, Yang F, Li X, Wang H, Lui M, Lo C, Leung B, Khong P, Hui C, Yuen K, Kuo M. Imaging profile of the COVID-19 infection: Radiologic findings and literature review. *Radiology Cardiothorac Imaging* 2020.