

Modern Dressings for the Treatment of Chronic Wounds and the Family Doctor - Case Reports

Dragan Marinkovic

Health Center Negotin, Adult Health Protection Service, Negotin, Republic of Serbia

Email address:

drdragan303899@gmail.com

To cite this article:

Dragan Marinkovic. Modern Dressings for the Treatment of Chronic Wounds and the Family Doctor - Case Reports. *Journal of Family Medicine and Health Care*. Vol. 9, No. 1, 2023, pp. 1-6. doi: 10.11648/j.jfmhc.20230901.11

Received: December 4, 2022; **Accepted:** December 28, 2022; **Published:** January 9, 2023

Abstract: The appearance of modern dressings for the treatment of chronic wounds with the concept of moist wound healing has brought a completely new doctrine of their treatment, enabling significantly faster healing and thus a number of other benefits for health systems and health workers, patients with chronic wounds, and for society as a whole, reducing treatment costs drastically. The greatest benefit from their use is achieved by patients with chronic wounds, bearing in mind that a chronic wound significantly reduces and impairs the quality of life of patients. What makes modern dressings for the treatment of chronic wounds special is their simple use, which enables even family doctors to successfully treat chronic wounds with modern dressings, when the location of the wound itself and the involvement of frozen tissue allow it. They can be applied in the doctor's offices as well as in the patients' homes by the patrol services. Their application can be of particular importance to patients in rural areas where the health care system is more difficult to access and where the appointments of health workers, doctors and nurses are not daily. In those cases, patients, as well as their family members, can be educated to apply modern dressings for the treatment of chronic wounds by themselves with occasional control examinations by health workers.

Keywords: Family Doctor, Wound Treatment, Modern Dressings, Primary Health Care

1. Introduction

The skin is the largest organ in the human body, forming not only the first line of defense against environmental factors, but also one of the organs that receives information from the environment that surrounds us. [1-4] Due to the action of various forces, the continuity of the skin or mucous membrane can be interrupted and wounds may appear.[5, 6] Those wounds that do not heal using standard treatment procedures within a month or longer are called chronic. [7, 8, 13, 21] Wound healing is a dynamic and complex process that starts from the moment the injury occurs, i.e. the coagulation phase, then the inflammation phase, the proliferation phase and the remodeling phase. [3-5, 7, 8, 13, 14, 18] Wound treatment aims to restore the damaged integrity and functions of the skin. The healing process itself can be complicated by local factors such as pressure, swelling, infection and systemic factors, which include age, malnutrition, chronic diseases, diabetes. It is estimated that in Europe approximately two million people live with a chronic wound, in the USA 2% of the adult population has a chronic wound, while the health systems of

modern societies allocate 3% of their budgets for the treatment of chronic wounds. [6, 9-12, 19, 21].

The concept of moist wound healing with the use of modern dressings today represents the standard in the treatment of chronic wounds, achieving what is unique to them and making them superior to the previous dressing and treatment of chronic wounds with cotton gauze, which is the achievement of autolytic debridement of the wound. [3, 8, 13, 15] Wound debridement is a procedure for removing non-viable tissue from a wound, where autolytic debridement is also the simplest form of debridement that can be applied even at the primary level of health care. [3, 7, 13, 14, 17, 22] Also, a number of other advantages are found on the side of modern dressings for the treatment of chronic wounds. Their use is atraumatic and their removal painless for the patient. One of the basic roles of any modern dressing is to create conditions for moist wound healing through the creation of a controlled moist environment by the dressing itself, which creates conditions for the proliferation of cells necessary for epithelialization and wound healing [17]. The peculiarity of modern dressings for the treatment of wounds is that, with

their conception and structure, they enable the exchange of gases with the external environment and, therefore, an adequate local immune response. [3, 8, 15, 16]. At the same time, they prevent the penetration of microorganisms and liquids from the external environment, enabling better infection control. The necessary amount of moisture is retained in the wound itself, which enables the creation of fibroblasts, macrophages and growth factors, and the migration of keratinocytes from the edges of the wound. [4, 13, 15] All dressings, including cotton ones, provide early physical protection against possible re-injury, with the fact that there is a significant difference between cotton gauze and modern dressings, where modern dressings for wound treatment and their application have a significant advantage over cotton gauze. [3, 8, 15] Namely, drying the cotton gauze prolongs the inflammatory response with stimulation of neutrophils and slowed angiogenesis due to the lack of fibroblasts and macrophages and therefore growth factors. By removing the dried cotton gauze, the cells necessary for epithelialization are also removed. [3, 4, 8, 15] In the treatment of chronic wounds with modern dressings, cotton gauze can be used as a secondary dressing. Today, hundreds of modern coverings from various manufacturers are available. They began their expansion in the eighties of the last century, to be followed by the peak in the mid-nineties and whose development continues continuously. [6, 8, 10, 13] According to permeability to water and water vapor, modern dressings are divided into semi-occlusive, which includes polyurethane films and foams, alginate dressings, and occlusive, hydrogels and hydrocolloid dressings. [3, 13, 15] They have the properties mentioned above that make them superior to cotton gauze, which is a non-occlusive dressing, completely permeable to water and fluids from the external environment as well as water vapor, which is in complete contrast to the concept of moist wound healing. In light of the use of modern dressings in the treatment of chronic wounds, cotton gauze can be used as a secondary dressing in the absence of a modern dressing that is applied as a secondary dressing.

Polyurethane foam dressings are widely used multi-layer semi-occlusive dressings. The internal, hydrophilic polyurethane foam component has a high absorptive power with a wide range of uses starting from cuts, superficial burns, venous and diabetic ulcers to infected wounds with abundant exudate. [3, 8, 15, 16] The presence of a chronic wound is a circumstance that has a devastating impact on the patient's quality of life, taking into account that it often leads to amputation of the affected limb in diabetics. [4, 9, 12, 13, 16, 18, 21, 22] A patient with a chronic wound becomes difficult to move and therefore asocial, excluded from daily activities, which induces anxiety and depression. The presence of pain due to a chronic wound is a particularly aggravating factor. [4, 8, 9, 13, 16] The choice and use of an adequate dressing contributes to reducing the intensity of pain, along with infection control. [7, 8, 10, 17, 21, 22] In the circle of those who are faced with a chronic wound and its treatment, doctors and nurses who work as a team at the level of primary health care, patients and their families, modern dressings and

their use form an indispensable segment. The ease of use of modern dressings can especially be expressed in patients in rural areas and in circumstances of difficult access to the health care system. [7, 10] The attending physician or team nurse (district nurse) can educate the family of a patient with a chronic early debridement procedure with a modern dressing. [6, 7, 9, 10, 19] This achieves enormous savings, taking into account the funds that would have to be set aside for transporting the patient to surgical clinics of health institutions or doctors' offices for debridement of the wound, or visiting nurses for debridement in home conditions, as well as eventual hospitalization of the patient.

2. Case Reports

2.1. Presentation of Case No. 1

A 51-year-old female patient presents to her family doctor because of a chronic wound-ulcer caused by an injury to the back of her left lower leg. On examination, she is conscious, oriented and mobile, with no significant health problems. The patient is originally from a rural area, significantly far from her home healthcare institution, and insists that the treatment of the chronic wound be carried out in the outpatient clinic of the family doctor.

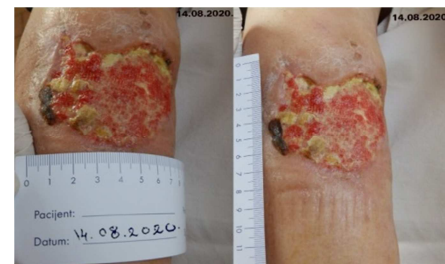

Figure 1. Chronic leg ulcer in the inflammatory phase of wound healing.

14.08.2020. Chronic wound of the back of the left lower leg after an injury. The wound has irregular edges, the wound bed is filled with granulation tissue with fibrin deposits. The patient is advised to debride the chronic wound with a polyurethane dressing with topical application of fusidic acid.

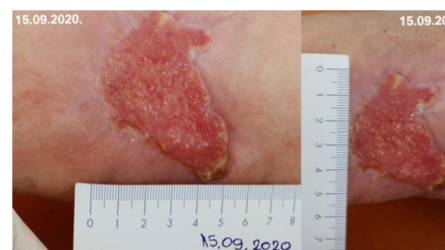

Figure 2. Proliferation phase with the granulation tissue in the wound bed.

15.09.2020. Wound after one-month debridement with polyurethane foam dressing and topical application of fusidic acid. The wound bed is filled with healthy granulation tissue while the wound itself is noticeably smaller in size due to the migration of cells necessary for epithelialization from the edges of the wound. The wound shows a tendency to heal

precisely because of debridement, which achieves the concept of "controlled humidity", that is, by establishing a moist environment using modern polyurethane foam dressing. Chronic wound debridement is continued by cleaning the wound with the application of a modern dressing that is changed every fourth day.

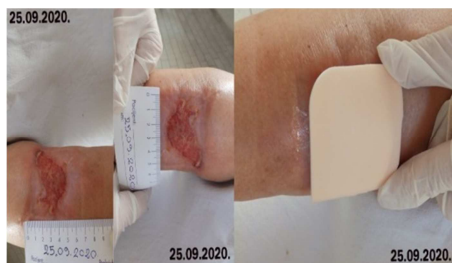

Figure 3. Autolytic debridement with polyurethane dressing in the family doctor's office.

25.09.2020. Debridement of a chronic wound with a polyurethane foam dressing, with prior obligatory cleaning of the wound with a saline solution. A chronic wound of an irregular shape filled with granulations due to the establishment of angiogenesis and the synthesis of cells necessary for granulation and the formation of epithelium on the edges of the wound. The wound is almost twice as small compared to the start of treatment in mid-August 2020.

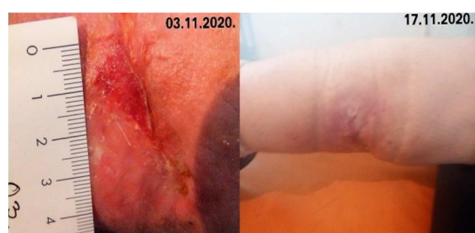

Figure 4. Remodeling phase of chronic wound.

03.11.2020. / 17.11.2020. The formation of a scar as well as the achievement of complete epithelization and healing of the wound after a three-month treatment with a modern dressing for the treatment of chronic wounds - a polyurethane foam dressing and the initial topical application of fusidic acid. As of the end of 2020, that is, after the wound was closed, the wound showed no signs of recurrence.

2.2. Presentation of Case No. 2

The patient is 73 years old, a long-term insulin-dependent diabetic. The patient's family asks the family doctor for an examination at the patient's home due to the patient's poor general condition and difficult mobility, and due to the development of a decubitus ulcer on the patient's back. On examination, the patient is conscious, difficult to move, takes a passive position in bed. He suffered a myocardial infarction, has stenosis of both internal carotid arteries, occlusive aortoiliac disease and generalized arteriosclerosis. Two years ago, due to an attack of vertigo, the inability to walk independently and the development of left-sided weakness, the existence of an inoperable glial tumorous change was established by magnetic

resonance imaging of the endocranium.

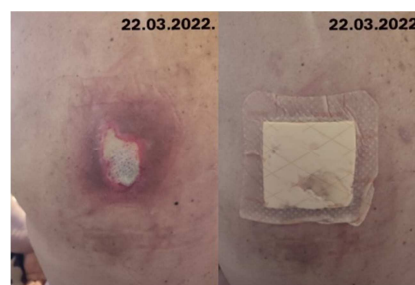

Figure 5. Polyurethane foam adhesive border dressing on pressure ulcer.

22.03.2022. Second-degree decubitus ulcer localized on the patient's back.[17, 22] A decubitus ulcer is irregular in shape, filled with fibrin and locally discolored skin that is dark red in color. Treatment of the decubitus ulcer is started immediately with the topical application of fusidic acid locally and debridement with a polyurethane foam dressing.

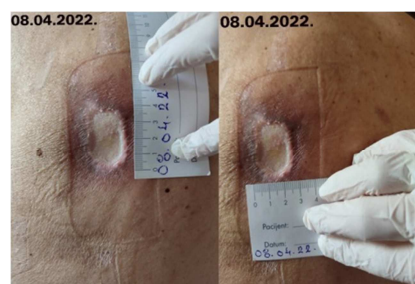

Figure 6. Decubitus with regular edges with a fibrin deposit in the wound bed after two-week debridement.

08.04.2022. Decubitus ulcer after two-week debridement with polyurethane dressing. The decubitus takes an elliptical shape, the edges of the decubitus are regular while the wound bed is filled with fibrin deposits. The ulcer itself is significantly smaller in size. Periwound, on the skin, the edges of the placed dressing are visible, which is now shaped in accordance with the size and dimensions of the ulcer. Also, the periwound skin color changes from dark red to a normal color. After the initial topical application of fusidic acid, debridement continues with the cleaning of the chronic wound and the application of a modern dressing.

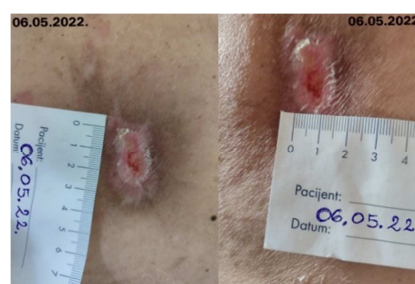

Figure 7. Migration of epithelial cells from the edges of decubitus.

06.05.2022. Epithelialization of decubitus ulcer. The newly formed skin is lighter, slightly pink in color compared to the dermis surrounding the decubitus ulcer. Polyurethane

dressing was changed every fourth day with mandatory pre-cleaning of the wound before application of the dressing.

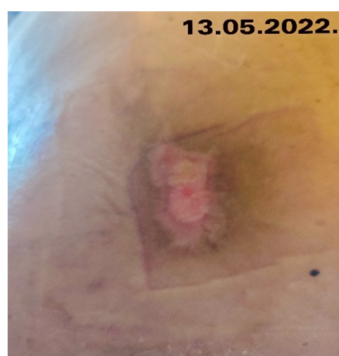


Figure 8. Completely healed decubitus ulcer by treatment at the level of primary health care – at patients home.

13.05.2022. After an incomplete two-month treatment, the healing of the chronic wound - decubitus ulcer is achieved using modern polyurethane foam dressing. The newly formed skin is lighter in color, thinner and less pigmented than the skin surrounding the ulcer.

2.3. Presentation of Case No. 3

A 75-year-old female patient with a pressure ulcer on the lateral side of the left lower leg. The patient is a chronic heart patient, immobile due to left hemiplegia after a cerebrovascular insult. The patient's family insists that pressure ulcer debridement be performed at home.

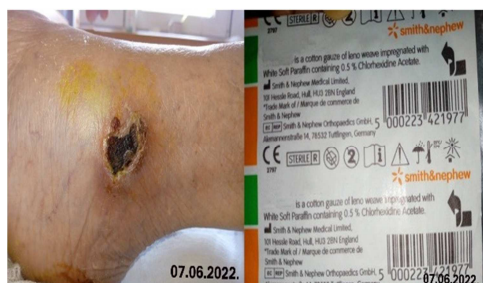

Figure 9. Pressure ulcer with irregular edges filled with non-viable tissue and non-adherent dressing with antiseptic.

07.06.2022. Decubitus on the lateral side of the left lower leg. Debridement is carried out by applying a paraffin dressing impregnated with chlorhexidine with prior cleaning of the decubitus with saline solution. The lining is changed every third day.

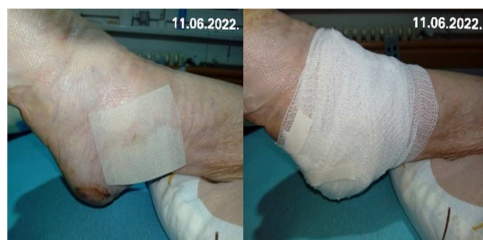

Figure 10. Primary (paraffin) and secondary dressing (cotton gauze) in the treatment of chronic wounds.

11.06.2022. Paraffin dressing impregnated with an antiseptic is used as a primary dressing, while cotton gauze is used as a secondary dressing.

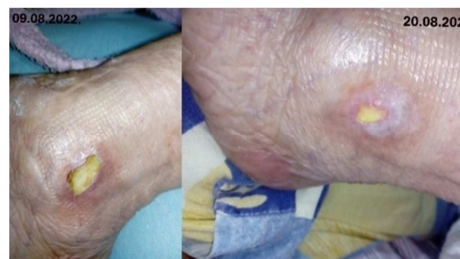

Figure 11. Healing of a chronic wound with autolytic debridement, performed in home conditions.

09.08.2022/20.08.2022. Decubitus ulcer after a two-month debridement with a paraffin dressing impregnated with an antiseptic. It is twice as small in size with a tendency to heal and close chronic wound.

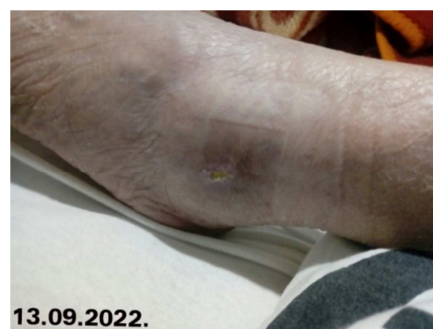

Figure 12. Chronic wound almost completely closed by the concept of moist wound healing.

13.09.2022. Healing and epithelization of a chronic decubitus wound localized on the lateral side of the left lower leg was achieved after a three-month debrydman using a paraffin dressing impregnated with an antiseptic.

3. Discussion

All presented patients were successfully treated at the primary level of health care with modern dressings for the treatment of chronic wounds, where epithelialization and healing were achieved in a relatively short period of time. Debridement of a chronic wound patient from case report no. 3 was carried out by her family, while the instructions on the choice of dressing in order to achieve the concept of moist healing of the wound with autolytic debridement, as well as the wound cleaning procedure, the application of the dressing, were carried out by the family doctor.[22] It is precisely the treatment of the patient from the presentation number 3 that is an example of achieving enormous savings and relief for the healthcare system. Completely successful treatment using a dressing that achieves the concept of moist wound healing was carried out by the patient's family, in which the choice of modern dressing was adjusted to their own financial capabilities in cooperation with their chosen doctor.[22] For

all chronic wounds, it is considered that they are colonized by polymicrobial bacterial flora, of which are the most common *Staphylococcus Aureus*, *Pseudomonas Aeruginosa*, β hemolytic streptococcus, and empiric treatment with topical and, when necessary, systemic antibiotic therapy is often necessary. [4, 10, 15] Fusidic acid with its staphylocidal effect applied topically proved to be an adequate choice in all patients presented. [3, 10, 15, 20] Also applied antiseptic for topical application is chlorhexidine, which impregnated paraffin gauze used in the treatment of chronic leg ulcers of the female patient in case report no. 3. Taking into account the complexity of the healing process itself, as well as the fact that a chronic wound is often a complication of an underlying disease, a holistic approach to a patient with a chronic wound is necessary for successful treatment, i.e. treating not only the wound, but treating and eliminating the causes that caused it. [3, 4, 7, 9].

4. Conclusion

Acquaintance and education of healthcare workers with the advantages that the treatment of chronic wounds with modern dressings brings is a necessity due to the achievement of accelerated healing and the achievement of epithelization, which represents a significant financial relief for healthcare systems. For a patient with a chronic wound, successful treatment represents a significant step towards establishing the previous quality of life, but it is very important to note that successful treatment is also a relief for the families of patients with chronic wounds. Approaching the concept of wet wound healing with the concept of controlled humidity with modern dressings for the treatment of chronic wounds not only to health workers, but also to patients and their families is a necessity in order to promote a unique concept of treatment that is successfully achievable and applicable both in hospital conditions, doctor's offices as well as in patients' homes.

References

- [1] Grice EA, Segre JA. The skin microbiome. *Nat Rev Microbiol.* [Internet]. 2011 [cited 2022 Jun 12]. Apr; 9 (4): 244-53. Erratum in: *Nat Rev Microbiol.* 2011 Aug; 9 (8): 626. Available from: <https://www.ncbi.nlm.nih.gov/pmc/articles/PMC3535073/>
- [2] Wong R, Geyer S, Weninger W, Guimbeteau JC, Wong JK. The dynamic anatomy and patterning of skin. *Exp Dermatol.* [Internet]. 2016 Feb [cited 2022 Jun 18]; 25 (2): 92-8. Available from: <https://onlinelibrary.wiley.com/doi/10.1111/exd.12832>
- [3] Han G, Ceilley R. Chronic Wound Healing: A Review of Current Management and Treatments. *Adv Ther* [Internet]. 2017 Mar [cited 2022 Jul 19]; 34 (3): 599-610 Available from <https://pubmed.ncbi.nlm.nih.gov/28108895/>
- [4] Zhao R, Liang H, Clarke E, Jackson C, Xue M. Inflammation in Chronic Wounds. *Int J Mol Sci.* [Internet]. 2016 Dec 11 [cited 2022 Aug 2]; 17 (12): 2085. Available from: <https://www.ncbi.nlm.nih.gov/pmc/articles/PMC5187885/>
- [5] Wang PH, Huang BS, Horng HC, Yeh CC, Chen YJ. Wound healing. *J Chin Med Assoc.* [Internet]. 2018 Feb [cited 2022 Jun 27]; 81 (2): 94-101 Available from: <https://pubmed.ncbi.nlm.nih.gov/29169897/>
- [6] Giaquinto-Cilliers MGC, Nair A, Von Pressentin KB, Coetzee F, Saeed H. A 'game of dressings': Strategies for wound management in primary health care. *S Afr Fam Pract* [Internet]. (2004). 2022 Feb [cited 2022 Aug 14] 28; 64 (1): e1-e8. Available from: <https://www.ncbi.nlm.nih.gov/pmc/articles/PMC8905468/pdf/SAF-P-64-5462.pdf>
- [7] Eriksson E, Liu PY, Schultz GS, Martins-Green MM, Tanaka R, Weir D, Gould LJ, Armstrong DG, Gibbons GW, Wolcott R, Olutoye OO, Kirsner RS, Gurtner GC. Chronic wounds: Treatment consensus. *Wound Repair Regen* [Internet]. 2022 Mar [cited 2022 Sep 2]; 30 (2): 156-171 Available from: <https://pubmed.ncbi.nlm.nih.gov/35130362/>
- [8] Dhivya S, Padma VV, Santhini E. Wound dressings - a review. *Biomedicine (Taipei)* [Internet]. 2015 Dec [Cited 2022 Sep 9]; 5 (4): 22 Available from: <https://pubmed.ncbi.nlm.nih.gov/26615539/>
- [9] Friman A, Edström DW, Edelbring S. General practitioners' perceptions of their role and their collaboration with district nurses in wound care. *Prim Health Care Res Dev* [Internet]. 2018 Jul 19 [cited 2022 Sep 22]; 20: e39 Available from: <https://www.ncbi.nlm.nih.gov/pmc/articles/PMC6536755/>
- [10] Sen CK. Human Wounds and Its Burden: An Updated Compendium of Estimates. *Adv Wound Care* (New Rochelle). [Internet]. 2019 Feb [cited 2022 Sep 14] 1; 8 (2): 39-48. Available from: <https://www.ncbi.nlm.nih.gov/pmc/articles/PMC6389759/>
- [11] Martinengo L, Olsson M, Bajpai R, Soljak M, Upton Z, Schmidtchen A, Car J, Järbrink K. Prevalence of chronic wounds in the general population: systematic review and meta-analysis of observational studies. *Ann Epidemiol.* [Internet]. 2019 Jan; 29: 8-15. Available from: <https://spiral.imperial.ac.uk/handle/10044/1/66134>
- [12] Lindholm C, Searle R. Wound management for the 21st century: combining effectiveness and efficiency. *Int Wound J* [Internet]. 2016 [cited 2022 Sep 18] Jul; 13 Suppl 2 (Suppl 2): 5-15 Available from: <https://www.ncbi.nlm.nih.gov/pmc/articles/PMC7949725/pdf/IWJ-13-5.pdf>
- [13] Munro G. Causes and consideration with chronic wounds: a narrative review of the evidence *Wound Practice and Research* [Internet]. 2017 Jun [cited 2022 Sep 30] 25 (2): 88-97 Available from: <https://journals.cambridge.org/au/application/files/5415/8501/5383/munro.pdf>
- [14] Wilkinson HN, Hardman MJ. Wound healing: cellular mechanisms and pathological outcomes. *Open Biol.* [Internet]. 2020 Sep; [cited 2022 Sep 28] 10 (9): 200223. Available from: <https://www.ncbi.nlm.nih.gov/pmc/articles/PMC7536089/>
- [15] Nuutila K, Eriksson E. Moist Wound Healing with Commonly Available Dressings. *Adv Wound Care* (New Rochelle) [Internet]. 2021 Dec [cited 2022 Aug 18]; 10 (12): 685-698 Available from: <https://pubmed.ncbi.nlm.nih.gov/32870777/>
- [16] Tiscar-González V, Menor-Rodríguez MJ, Rabadán-Sainz C, Fraile-Bravo M, Styche T, Valenzuela-Ocaña FJ, Muñoz-García L, Life Group. Clinical and Economic Impact of Wound Care Using a Polyurethane Foam Multilayer Dressing. *Adv Skin Wound Care* [Internet]. 2021 Jan; [cited 2022 Jun 2] 34 (1): 23-30 Available from <https://pubmed.ncbi.nlm.nih.gov/33323799/>

- [17] Podd, Daniel MPAS, PA-C. Beyond skin deep: Managing pressure injuries. JAAPA: [Internet]. April 2018 [cited 2022 Sep 28] - Volume 31 - Issue 4 - p 10-17 Available from: https://journals.lww.com/jaapa/Fulltext/2018/04000/Beyond_skin_deep__Managing_pressure_injuries.2.aspx
- [18] Gould L, Abadir P, Brem H, Carter M, Conner-Kerr T, Davidson J, DiPietro L, Falanga V, Fife C, Gardner S, Grice E, Harmon J, Hazzard WR, High KP, Houghton P, Jacobson N, Kirsner RS, Kovacs EJ, Margolis D, McFarland Horne F, Reed MJ, Sullivan DH, Thom S, Tomic-Canic M, Walston J, Whitney JA, Williams J, Zieman S, Schmader K. Chronic wound repair and healing in older adults: current status and future research. J Am Geriatr Soc [Internet]. 2015 Mar [cited 2022 Jul 4]; 63 (3): 427-38 Available from: <https://pubmed.ncbi.nlm.nih.gov/25486905/>
- [19] Little SH, Menawat SS, Worzniak M, Feters MD. Teaching wound care to family medicine residents on a wound care service. Adv Med Educ Pract [Internet]. 2013 Aug (Cited 2022 Sep 2) 19; 4: 137-44 <https://pubmed.ncbi.nlm.nih.gov/23983497>
- [20] Gajdács M. The Continuing Threat of Methicillin-Resistant Staphylococcus aureus. Antibiotics (Basel) [Internet]. 2019 May 2 [cited Jul 30]; 8 (2): 52. Available from: <https://pubmed.ncbi.nlm.nih.gov/31052511/>
- [21] Olsson M, Järbrink K, Divakar U, Bajpai R, Upton Z, Schmidtchen A, Car J. The humanistic and economic burden of chronic wounds: A systematic review. Wound Repair Regen. [Internet]. 2019 Jan [cited 2022 Sep 28]; 27 (1): 114-125. Available from: https://spiral.imperial.ac.uk/bitstream/10044/1/65563/2/Carr.Wound_Repair_and_Regeneration.pdf
- [22] Bhattacharya S, Mishra RK. Pressure ulcers: Current understanding and newer modalities of treatment. Indian J Plast Surg. [Internet]. 2015 Jan-Apr; 48 (1): 4-16. Available from: <https://www.thieme-connect.com/products/ejournals/html/10.4103/0970-0358.155260>