

Nonspecific Lesions in Patients with Chronic Vulvar Discomfort Revealed Vulvodynia as Chronic Reflex Pain Syndrome (CRPS) Type I

Vesna Harni^{1,*}, Damir Babic², Suzana Ljubojevic-Hadzavdic³, Dubravko Barisic⁴

¹Department of Obstetrics and Gynaecology, Polyclinic Harni, Zagreb, Croatia

²Department of Pathology and Cytology, University Hospital Center, Zagreb, Croatia

³Department of Dermatovenereology, University Hospital Center, Zagreb, Croatia

⁴Department of Obstetrics and Gynaecology, Kardinal Schwarzenberg Klinikum GmbH, Schwarzach im Pongau, Austria

Email address:

vesnaharni@gmail.com (Vesna Harni), babic.damir@gmail.com (Damir Babic),

suzana.ljubojevic@gmail.com (Suzana Ljubojevic-Hadzavdic), dub.barisic@gmail.com (Dubravko Barisic)

*Corresponding author

To cite this article:

Vesna Harni, Damir Babic, Suzana Ljubojevic-Hadzavdic, Dubravko Barisic. Nonspecific Lesions in Patients with Chronic Vulvar Discomfort Revealed Vulvodynia as Chronic Reflex Pain Syndrome (CRPS) Type I. *Journal of Gynecology and Obstetrics*. Vol. 10, No. 6, 2022, pp. 243-252. doi: 10.11648/j.jgo.20221006.12

Received: October 16, 2022; **Accepted:** November 3, 2022; **Published:** November 10, 2022

Abstract: This study aimed to investigate the presence, type, and arrangement of nonspecific lesions considering the different histologies of the three vulvar rings in women with chronic vulvar discomfort to obtain reference data for the diagnostic procedure and a better understanding of women with chronic vulvar distress. The distribution of nonspecific lesions in the vulva based on vulvar rings was monitored as a secondary outcome measure within the framework of the prospective experimental study using diagnostic interventions called DATRIV, which included a total of 328 consecutive participants. Four patient groups were distinguished according to their medical history, structured International Society for the Study of Vulvovaginal Disease vulvodynia questionnaire results, and clinical examination, including inspection and cotton swab test. Asymptomatic participants were classified into normal vulva (N = 82) and impaired vulvar skin (N = 82) groups. Patients with chronic vulvar discomfort were categorized into groups of patients with primary, idiopathic vulvar distress/vulvodynia (N=82), and secondary complaints caused by vulvar dermatosis (N=82). Three rings vulvoscopy form data were used to collect clinical data, which were analyzed using StatSoft (Dell, Austin, TX, USA), Statistica 12 (TIBCO®, Palo Alto, CA, USA), and SPSS 20 (IBM, Armonk, NY, USA). This study was approved by the Institutional Review Board of Polyclinic Harni, and all patients provided written informed consent. Nonspecific changes in the outer vulvar ring were significantly more common in patients with vulvar dermatosis (70.7%). The opposite pattern of lesion incidence was observed, with a considerably higher frequency of nonspecific findings in the inner vulvar ring in patients with vulvodynia (98.8%) and impaired vulvar skin (96.3%). The inner vulvar ring in patients with vulvodynia demonstrated a peculiar and characteristic profile with significantly more frequent findings of erythema (92.7%), punctuations (54.9%), ischemia (48.8%), and papillae (25.6%). A high presence of nonspecific lesions in the middle vulvar ring was documented in all participants, with an evident distinction in the appearance and allocation of these findings between patients with vulvodynia and vulvar dermatosis. By establishing the characteristic pattern of the type and distribution of nonspecific lesions in patients with vulvodynia, the Budapest criteria for considering vulvodynia as chronic reflex pain syndrome (CRPS) type I, formerly sympathetic dystrophy, are met. Due to the specific three rings anatomy of the vulva, revised Budapest criteria are proposed. This study creates a unique opportunity to introduce vulvoscopy in the differential diagnosis of chronic, primary, and secondary vulvar discomfort.

Keywords: Vulvar Discomfort, Vulvodynia, Vulvar Dermatitis, Three Rings Vulvoscopy, Vulvar Lesions, Chronic Reflex Pain Syndrome (CRPS), Budapest Criteria

1. Introduction

In recent years, there has been a considerable shift in the understanding and interpretation of vulvar discomfort, described mainly as vulvar pain. Vulvar pain is a set of various symptoms, including burning, stinging, soreness, irritation, stabbing, sticking, a paper cut feeling, a knife cut feeling, itching, and aching, according to the terminology and classification of vulvodynia proposed by the International Society for the Study of Vulvovaginal Disease (ISSVD) [1, 2].

Current changes distinguish primary, idiopathic pain without explicit causation and secondary vulvar pain caused by a specific disease such as vulvar dermatosis. Idiopathic pain, classified as vulvodynia, occurs for no explicit reason, lasts for at least three months, and may be associated with additional conditions. While the basis of vulvar pain is not obviously concordant with the definition of vulvodynia, various factors, such as genetic, hormonal, inflammatory, musculoskeletal, and neurological factors, are associated with the development of this condition [3].

The changes in definitions are due to a consensus on pelvic pain terminology among the ISSVD, the International Society for the Study of Women's Sexual Health (ISSWSH), the International Pelvic Pain Society (IPPS), and representatives of the American Congress of Obstetricians and Gynecologists (ACOG), the American Society for Colposcopy and Cervical Pathology (ASCCP) and the National Vulvodynia Association (NVA) in 2015 [3].

However, the precise mechanisms involved in the pathophysiology of chronic pain are complex and remain unclear. This is further emphasized by the International Association for the Study of Pain (IASP) description of pain as an unpleasant and emotional experience associated with actual or potential tissue damage or described in terms of such damage, or both [4, 5].

Vulvoscopy as a diagnostic method was introduced to aid the evaluation of vulvar complaints [6, 7]. However, although the classification of findings in the vulva is the same as that used for the cervix and vagina, it is uncertain whether these lesions have the same importance in vulvoscopy as in colposcopy [8–10]. The reason for this is the lack of comparative studies on the distribution of nonspecific vulvar lesions in women without vulvar distress, which makes it challenging to distinguish vulvar physiology from pathology. Due to this issue, the presence and distribution of nonspecific lesions in the vulva were recorded within the DATRIV study, promoting a new technique of vulvoscopy according to the anatomical and histological structures of the vulva, arranged in three rings [11, 12].

This study aimed to evaluate the distribution of nonspecific findings according to the three vulvar rings in women with chronic vulvar discomfort compared with healthy women without vulvar complaints to obtain reference data needed in the diagnostic process and a better understanding of women with chronic vulvar distress.

2. Methods

2.1. Study Design

The distribution of nonspecific lesions according to vulvar rings was monitored as a secondary outcome measure in a prospective experimental study using diagnostic interventions called the DATRIV study, which included a total of 328 consecutive participants [11, 12]. The study distinguished two groups of patients, those with symptoms of vulvar discomfort (N = 164) and asymptomatic patients (N = 164), based on patient history and the ISSVD Vulvodynia Pattern Questionnaire. An asymptomatic patient was randomly assigned to each symptomatic patient. Exclusion criteria were vulvar infection, benign tumors, pre-/malignancy, incomplete medical records, and protocol violation. This study was conducted at the Polyclinic Harni in Zagreb, Croatia, between December 1, 2011, and December 31, 2016.

Patients with chronic vulvar discomfort were categorized into two groups, those with idiopathic vulvar pain/vulvodynia (N=82) and those with secondary vulvar discomfort caused by vulvar dermatosis (N=82). According to the existing classification, vulvodynia was diagnosed according to Friedrich's criteria [13–15]. Therefore, the vulvar lesions found in patients with vulvodynia were irrelevant to the diagnosis.

Vulvar dermatosis was diagnosed by finding lesions with a secondary morphological presentation called "specific lesions" [9, 16]. Specific lesions implied a finding of an eczematous inflammation with thickened, excoriated skin (red, flat, and diffuse lesions on the vulvar skin); hypopigmented or white lesions (irregularly and extensively diffuse white plaques and patches on skin and mucosa); white reticular pattern to extensive erosion, especially in the vestibule; erythematous papules with silver, scaly plaques, agglutination, and fusion; or resorption of the labia minora and clitoral hood, loss of vulvar architecture, and sclerotic changes [6, 8].

In addition to specific lesions, the presence and distribution of nonspecific lesions according to the three vulvar rings were evaluated. Nonspecific lesions included nonspecific erythema in any part of the vulva, punctuations and papillae, pallor, smoothness, and fissures of the vulvar mucosa. These were formerly described as findings suggestive of infectious and viral pathology [8, 17].

According to a previous observational study, based on clinical examination, inspection, and cotton swab test, asymptomatic participants were classified into the normal vulva group (N = 82) group if there were no changes in the vulva or impaired vulvar skin group (N = 82) if nonspecific changes in the vulva were observed [18]. The definition of a normal vulva was adopted from previous vulvoscopy classifications [6, 8, 16].

All four patient groups underwent three rings vulvoscopy (TRIV) and a vulvar biopsy with histopathology as diagnostic interventions. Vulvoscopy data were collected and

organized, and the lesions were precisely mapped in relation to the vulvar rings using the TRIV data form.

Biopsy of the vulva in symptomatic patients was performed as routine clinical care. Asymptomatic participants were recruited from asymptomatic women undergoing elective labiaplasty, and the vulvar biopsy was performed on vulvar samples approved for further investigation.

2.2. Data Analysis

Data were analyzed using software packages, including StatSoft (Dell, Austin, TX, USA), Statistica 12 (TIBCO®, Palo Alto, CA, USA), and SPSS 20 (IBM, Armonk, NY, USA). Basic statistics were performed, including calculating the mean (the arithmetic mean, quartiles, and mode) and measures of dispersion (variance and standard deviation).

A hypothesis that there would be differences among the distributions was also investigated. When the distribution of random variables was theoretically known, the appropriate parametric tests were used, and when the distribution was theoretically unknown, the proper nonparametric tests were used. The chi-square and Fisher's exact tests were used to measure the data on a nominal or ordinal scale. The t-test as a parametric test or the Mann-Whitney U test as a nonparametric test were used to test the difference in the distribution of the two continuous random variables.

2.3. Ethical Approval

All participants were informed that their participation was voluntary and that they had the right to refuse the questionnaire administration. The patients provided written informed consent for vulvoscopy and biopsy of the vulva. No incentive for participation was offered.

Ethical approval for this study was obtained from the Institutional Review Board of Polyclinic Harni, ethics approval number: 20111201001, dated December 1, 2011. In addition, the DATRIV study was registered at

ClinicalTrials.gov Identifier: NCT02732145 sign) removed.

3. Results

Nonspecific findings in the outer vulvar ring were significantly more common in patients with vulvar dermatosis (70.7%) than in other groups. The most significant finding was rhagades, especially on the labia majora and perineum, which were not found in any patient with vulvodynia, and excoriations, which were not registered in asymptomatic patients.

A detailed distribution of nonspecific lesions in the outer vulvar ring in patients with and without vulvar discomfort is shown in Table 1.

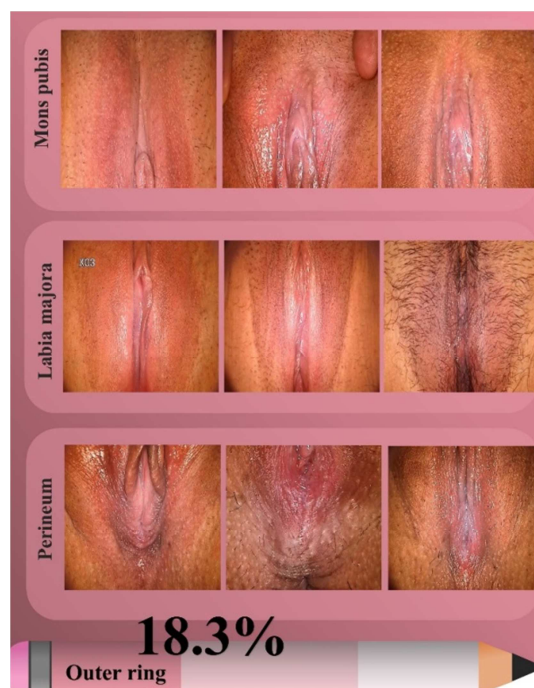

Figure 1. Distribution of nonspecific lesions in the outer vulvar ring in patients diagnosed with vulvodynia.

Table 1. Distribution of nonspecific lesions in patients with and without vulvar discomfort in the outer vulvar ring.

Outer vulvar ring	Normal vulva (82)	Impaired vulvar skin (82)	Vulvodynia (82)	Vulvar dermatosis (82)
Nonspecific lesions	0 (0%)	4 (4.9%)	15 (18.3%)	58 (70.7%)**
Erythema	0 (0%)	3 (3.7%)	12 (14.6%)	27 (32.9%)**
Excoriations	0 (0%)	0 (0%)	2 (2.4%)	23 (28.0%)**
Rhagades	0 (0%)	1 (1.2%)	0 (0%)	32 (39.0%)**
1) Mons pubis	0 (0%)	1 (1.2%)	2 (2.4%)	12 (14.6%)**
Erythema	0 (0%)	1 (1.2%)	2 (2.4%)	12 (14.6%)**
Excoriations	0 (0%)	0 (0%)	0 (0%)	9 (11.0%)**
Rhagades	0 (0%)	0 (0%)	0 (0%)	5 (6.1%)*
2) Labia majora	0 (0%)	1 (1.2%)	7 (8.5%)	38 (46.3%)**
Erythema	0 (0%)	1 (1.2%)	6 (7.3%)	24 (29.3%)**
Excoriations	0 (0%)	0 (0%)	0 (0%)	18 (22.0%)**
Rhagades	0 (0%)	0 (0%)	0 (0%)	12 (14.6%)**
3) Perineum	0 (0%)	4 (4.9%)	15 (18.3%)	51 (62.2%)**
Erythema	0 (0%)	3 (3.7%)	11 (13.4%)	20 (24.4%)**
Excoriations	0 (0%)	0 (0%)	2 (2.4%)	16 (19.5%)**
Rhagades	0 (0%)	1 (1.2%)	0 (0%)	28 (34.1%)**

*= $p < 0.05$; **= $p < 0.001$.

Figure 1 shows nonspecific lesions in the outer vulvar ring in patients with vulvodynia.

Table 2 shows the vulvoscopic findings on nonspecific changes in the middle vulvar ring. In summary, a high presence of nonspecific lesions in the middle vulvar ring was

recorded in all participants. There were no differences in the overall frequency of individual nonspecific lesions among the asymptomatic groups; however, some specific patterns were observed in patients with vulvodynia and vulvar dermatosis.

Table 2. Distribution of lesions in patients with vulvar discomfort in the middle vulvar ring.

Middle vulvar ring	Normal vulva (82)	Impaired vulvar skin (82)	Vulvodynia (82)	Vulvar dermatosis (82)
Nonspecific lesions	26 (31.7%)	71 (86.5%)*	79 (96.3%)*	68 (82.9%)
Erythema	26 (31.7%)	41 (50.0%)	62 (75.6%)**	45 (54.9%)
Fissures	0 (0%)	0 (0%)	2 (2.4%)	29 (35.4%)**
Smoothness / Loss of relief	0 (0%)	3 (3.7%)	0 (0%)	13 (15.9%)**
Punctuations	0 (0%)	1 (1.2%)	8 (9.8%)*	3 (3.7%)
1) Anterior commissure	1 (0%)	7 (8.5%)	9 (11.0%)	30 (36.6%)**
Erythema	0 (0%)	3 (3.7%)	3 (3.7%)	8 (9.8%)*
Fissures	0 (0%)	0 (0%)	0 (0%)	6 (7.3%)
Smoothness / Loss of relief	0 (0%)	0 (0%)	0 (0%)	9 (11.0%)**
Punctuations	0 (0%)	0 (0%)	0 (0%)	1 (1.2%)
2) Interlabial sulci	1 (1.2%)	32 (39.0%)	41 (50.0%)**	46 (56.1%)**
Erythema	0 (0%)	28 (34.1%)	35 (42.7%)	25 (30.5%)
Fissures	0 (0%)	0 (0%)	0 (0%)	12 (14.6%)**
Smoothness / Loss of relief	0 (0%)	1 (1.2%)	0 (0%)	11 (13.4%)**
Punctuations	0 (0%)	0 (0%)	0 (0%)	0 (0%)
3) Labia minora	10 (12.2%)	25 (30.5%)	48 (58.5%)**	42 (51.2%)**
Erythema	10 (12.2%)	9 (11.0%)	25 (30.5%)**	21 (25.6%)**
Fissures	0 (0%)	0 (0%)	0 (0%)	5 (6.1%)
Smoothness / Loss of relief	0 (0%)	1 (1.2%)	0 (0%)	6 (7.3%)*
Punctuations	0 (0%)	1 (1.2%)	3 (3.7%)	2 (2.4%)
4) Posterior commissure	23 (28.0%)	56 (68.3%)	76 (92.7%)**	56 (68.3%)
Erythema	23 (28.0%)	23 (28.0%)	48 (58.5%)**	33 (40.2%)
Fissures	0 (0%)	0 (0%)	2 (2.4%)	20 (24.4%)*
Smoothness / Loss of relief	0 (0%)	2 (2.4%)	0 (0%)	5 (6.1%)*
Punctuations	0 (0%)	0 (0%)	6 (7.3%)	1 (1.2%)

*= $p < 0.05$; **= $p < 0.001$.

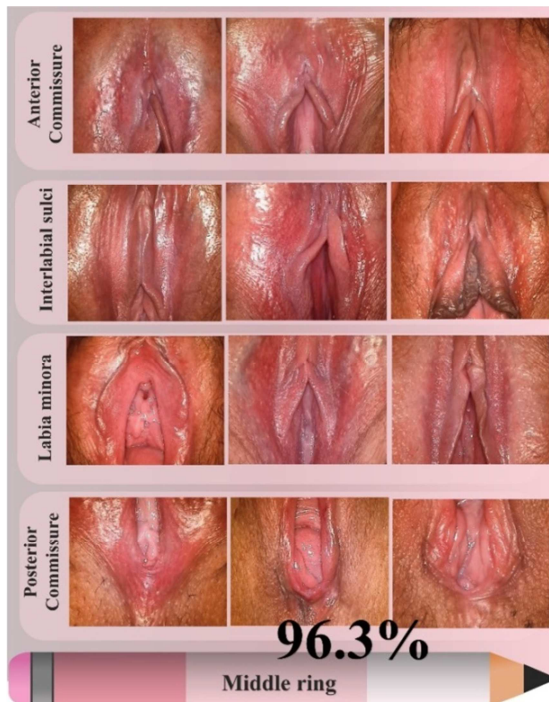

Figure 2. Localization of nonspecific lesions in the middle vulvar ring in patients diagnosed with vulvodynia.

In patients with vulvodynia, a significantly higher frequency of erythema and punctuations, especially erythema of the posterior commissure, was observed (Figure 2).

Patients with vulvar dermatosis had significantly more frequent fissures and skin smoothness/loss of satisfactory relief in all anatomical parts of the middle vulvar ring, nonspecific lesions in the anterior commissure, and fissures in the interlabial sulci and posterior commissure.

All participants had a high percentage of nonspecific lesions in the inner vulvar ring. The opposite pattern of lesion incidence was observed among the studied groups compared with the outer vulvar ring. Patients with vulvodynia (98.8%) and impaired vulvar skin (96.3%) had a significantly higher overall frequency of nonspecific findings than those with a normal vulva (39%) and vulvar dermatosis (85.4%).

The inner vulvar ring in patients with vulvodynia showed a peculiar and characteristic profile with significantly more frequent findings of erythema, punctuations, ischemia, and papillae (Figure 3).

The diagnosis of erythema or ischemia of the clitoris, erythema and punctuations of Hart's line, erythema and smoothness of the urethral sulcus, ischemia of the urethral meatus, Bartholin's gland opening erythema, and vestibular punctuations and papilla were particularly significant. Furthermore, some of these characteristics were also present

in asymptomatic patients with impaired vulvar skin, as shown in Table 3.

Table 3. Distribution of nonspecific lesions in patients with and without vulvar discomfort in the inner vulvar ring.

Inner vulvar ring	Normal vulva (82)	Impaired vulvar skin (82)	Vulvodynia (82)	Vulvar dermatosis (82)
Nonspecific lesions	32 (39%)	79 (96.3%)**	81 (98.8%)**	70 (85.4%)
Erythema	11 (13.4%)	61 (74.4%)	76 (92.7%)**	59 (72.0%)
Smoothness/Loss of relief	12 (14.6%)	23 (28.0%)	41 (5.0%)	28 (34.1%)**
Ischemia/Palor	6 (7.3%)	36 (43.9%)**	40 (48.8%)**	27 (32.9%)**
Punctuations	0 (0%)	36 (43.9%)	45 (54.9%)**	20 (24.4%)
Papillae	9 (11.0%)	21 (25.6%)**	21 (25.6%)**	2 (2.4%)
1) Clitoris	8 (9.8%)	43 (52.4%)	76 (92.7%)**	34 (41.5%)
Erythema	0 (0%)	11 (13.4%)	29 (35.4%)**	5 (6.1%)
Smoothness/Loss of relief	0 (0%)	5 (6.1%)	3 (3.7%)	11 (13.4%)**
Ischemia/Palor	0 (0%)	11 (13.4%)	14 (17.1%)*	8 (9.8%)
Punctuations	0 (0%)	0 (0%)	0 (0%)	0 (0%)
Papillae	0 (0%)	0 (0%)	0 (0%)	0 (0%)
2) Hart's line	21 (25.6%)	68 (82.9%)	81 (98.8%)**	55 (67.1%)
Erythema	11 (13.4%)	52 (63.4%)	69 (84.1%)**	43 (52.4%)
Smoothness/Loss of relief	1 (1.2%)	1 (1.2%)	1 (1.2%)	5 (6.1%)
Ischemia/Palor	1 (1.2%)	1 (1.2%)	4 (4.9%)	1 (1.2%)
Punctuations	0 (0%)	36 (43.9%)	43 (52.4%)**	12 (14.6%)
Papillae	8 (9.8%)	17 (20.7%)**	18 (22.0%)**	2 (2.4%)
3) Urethral sulcus	16 (19.5%)	69 (84.1%)	81 (98.8%)**	55 (67.1%)
Erythema	0 (0%)	26 (31.7%)	43 (52.4%)**	16 (19.5%)
Smoothness/Loss of relief	12 (14.6%)	22 (26.8%)	37 (45.1%)**	26 (31.7%)
Ischemia/Palor	4 (4.9%)	31 (37.8%)**	24 (29.3%)	21 (25.6%)
Punctuations	0 (0%)	3 (3.7%)	2 (2.4%)	0 (0%)
Papillae	0 (0%)	0 (0%)	2 (2.4%)	0 (0%)
4) Urethral meatus	7 (8.5%)	45 (54.9%)	72 (87.8%)**	43 (52.4%)
Erythema	1 (1.2%)	6 (7.3%)	18 (22.0%)**	20 (24.4%)**
Smoothness/Loss of relief	2 (2.4%)	2 (2.4%)	1 (1.2%)	6 (7.3%)*
Ischemia/Palor	2 (2.4%)	3 (3.7%)	9 (11.0%)*	2 (2.4%)
Punctuations	0 (0%)	1 (1.2%)	4 (4.9%)	4 (4.9%)
Papillae	0 (0%)	1 (1.2%)	0 (0%)	0 (0%)
5) Hymenal remnants	6 (7.3%)	37 (45.1%)	69 (84.1%)**	30 (48.8%)
Erythema	5 (6.1%)	7 (8.5%)	17 (20.7%)**	16 (19.5%)**
Smoothness/Loss of relief	1 (1.2%)	1 (1.2%)	0 (0%)	5 (6.1%)
Ischemia/Palor	0 (0%)	0 (0%)	4 (4.9%)	2 (2.4%)
Punctuations	0 (0%)	2 (2.4%)	5 (6.1%)	3 (3.7%)
Papillae	0 (0%)	1 (1.2%)	0 (0%)	0 (0%)
6) Bartholin's gland opening	8 (9.8%)	49 (59.8%)	77 (93.9%)**	33 (40.2%)
Erythema	7 (8.5%)	30 (36.6%)	49 (59.8%)**	24 (29.3%)
Smoothness/Loss of relief	1 (1.2%)	1 (1.2%)	0 (0%)	5 (6.1%)
Ischemia/Palor	0 (0%)	0 (0%)	3 (3.7%)	2 (2.4%)
Punctuations	0 (0%)	1 (1.2%)	4 (4.9%)	4 (4.9%)
Papillae	0 (0%)	0 (0%)	0 (0%)	0 (0%)
7) Vestibule	22 (26.8%)	59 (72.0%)	80 (97.6%)**	61 (74.4%)
Erythema	9 (11.0%)	29 (35.4%)	45 (54.9%)**	41 (50.0%)**
Smoothness/Loss of relief	3 (3.7%)	3 (3.7%)	4 (4.9%)	6 (7.3%)
Ischemia/Palor	6 (7.3%)	7 (8.5%)	14 (17.1%)*	8 (9.8%)
Punctuations	0 (0%)	8 (9.8%)	10 (12.2%)**	8 (9.8%)
Papillae	4 (4.9%)	12 (14.6%)*	10 (12.2%)*	1 (1.2%)

*=p<0.05; **=p<0.001,

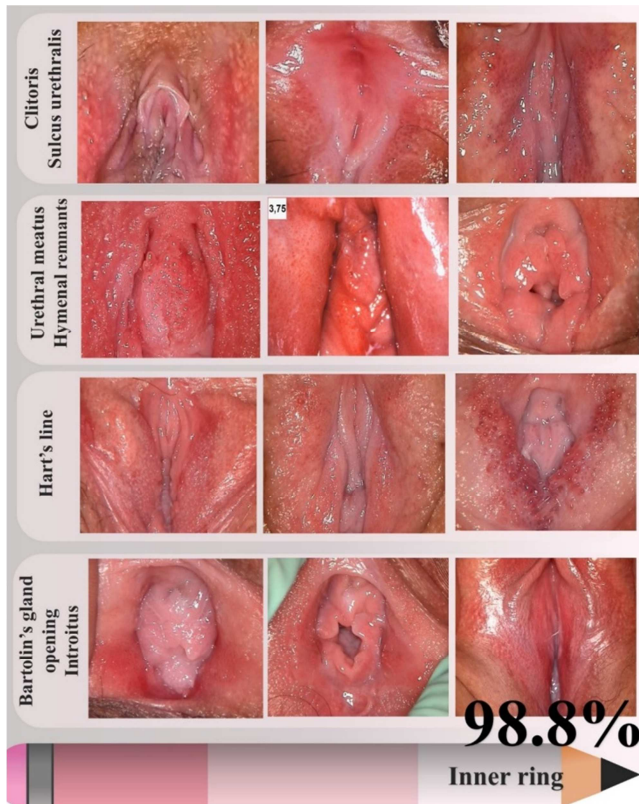


Figure 3. Nonspecific lesions and their distribution in the inner vulvar ring in patients diagnosed with vulvodynia.

4. Discussion

The suboptimal knowledge of practitioners and their experiences in teaching vulvar diseases through the development and affirmation of vulvology as a new subspecialty were not only recommendations and suggestions but the actual situation at the beginning of this millennium [19, 20].

Previous studies have shown that 79% of specialists have received training on vulvovaginal disorders through self-study. In comparison, only 19% have passed the training on vulvovaginal diseases during residency and 11% during fellowship [21, 22].

Most residency programs in Canada and the United States (93%) provide formal education on vulvovaginal diseases; however, clinical experience varies from site to site. Lack of training (71%) and interest (60%) are the most reported barriers to treating vulvar disorders [23].

The interdisciplinary nature of vulvology and the orchestrating of activities through the ISSVD have enabled the standardization and systematization of confusing terminologies and classifications applicable to vulvar disorders. Moreover, ISSVD plays a crucial role in promoting vulvar health care education among providers globally to create an effective worldwide change [22].

Unlike vulvology, vulvoscopy did not receive that kind of interest or flourishing and remained dormant. It was already indicated 30 years ago that colposcopic examination of the vulva

reveals abnormal images in 90% of patients with unresolved chronic vulvar symptoms, of which only 58% of lesions are detected using clinical examination or naked eyes [6].

Other studies did not attribute vulvoscopy to a profound perspective in diagnosing vulvar changes except as part of the evaluation of preinvasive or intraepithelial changes [7]. The description of vulvar lesions included two categories: (1) diffuse, irritative acetowhitening of the skin and mucosal surfaces and (2) painful vestibular erythema with or without acetowhitening [7, 17].

In addition, previous guidelines defined vulvodynia as "vulvar discomfort in the absence of relevant visible findings or a specific, clinically identifiable, and neurologic disorder" [14]. According to this definition, vulvodynia belongs to the group of nonmanifest and/or invisible diseases, and its diagnosis is made per exclusion. For this same reason, vulvoscopy was not used in differential diagnostics.

Despite this, one or more macroscopic abnormalities in patients with chronic vulvar discomfort (nonspecified) were observed in 58% of the women. The most common were nonspecific erythema and fissures and specific lesions such as papules and plaques. Papular or plaque-like lesions were usually associated with lichenification or an eczematous appearance and were in the hair-bearing areas of the vulva or perianal.

Patients with small fissures or erythema (22%), or both, which were solely limited to the mucosal surface, could easily be overlooked without careful examination under bright light [6].

While vulvodynia is considered an idiopathic pain disorder without an underlying substrate, most of the described findings on the vulva were nonspecific focal or diffuse vestibular erythema and tenderness of various degrees [24–27]. Along with vestibular erythema, a papillomatous appearance of mucosal surfaces [25] and erythema and tenderness of the opening of the Bartholin's gland have been described [28, 29]. The most pronounced erythema with increased superficial blood flow was in the posterior parts of the vestibular mucosa [30].

Insufficiently described nonspecific vulvar lesions were the reason for a systematic assessment of their presence, localization associated with the three vulvar rings, and investigation of the recurrence pattern regarding the type of vulvar complaints in a study that examined the diagnostic accuracy of three rings vulvoscopy. A recent analysis of the occurrence and type of nonspecific lesions associated with the three vulvar rings confirmed the accuracy of the suggestion that vulvar lesions should be investigated using the vulva's complex anatomy, histology, and embryology [8–10].

While the findings on specific lesions in the vulva are the most significant in the diagnosis of vulvar dermatosis, this study's results indicated a significantly more frequent nonspecific lesion in the outer (70.7%) and middle (82.9%) vulvar rings. It was most often erythema of the outer vulvar ring, smoothness of the skin with loss of proper relief, and fissure of the middle vulvar ring. This finding is not

surprising because dermatoses are skin diseases, and the outer and middle vulvar rings consist of skin and skin adnexa or modified skin.

Overall nonspecific changes in the inner vulvar ring were also present in 85.4% of patients with vulvar dermatosis. The underlying histological conditions are epithelial thinning, a well-defined inflammatory band, fibrosis with lymphocyte entrapment, abnormal thickened collagen, hyalinization, and scarring or loss of typical architecture [31, 32].

In contrast to vulvar dermatosis, patients with chronic vulvar discomfort diagnosed with vulvodynia had significantly fewer changes in the skin area of the outer vulvar ring (18.3%). Another significant result of this study was the presence of erythema (75.6%) and punctuations (9.8%) in the middle vulvar ring in patients with vulvodynia, which were 1.4 and 2.6 times more frequent, respectively, than in patients with vulvar dermatoses. The physiological basis for this was previously described by increased surface blood flow due to neurogenic vasodilatation [30].

Evaluating the inner vulvar ring under vulvoscopic magnification enabled recognition and clear distinction of ischemic areas (loss of color and pallor of tissue) and congestion (erythema). In addition, this study showed that nonspecific lesions in the inner vulvar ring were consistent characteristics of patients with vulvodynia (98.8%) and impaired skin of the vulva (96.3%), which were 15% and 12% more often, respectively, than in patients with vulvar dermatosis.

Erythema and punctuation were 1.28 and 2.25 times more frequent, respectively, in participants with vulvodynia than in those with vulvar dermatosis and 1.24 and 1.25 times more frequent, respectively, than in those with impaired skin of the vulva. Furthermore, Hart's line papillae were 916.6% and 862.5% more frequent in patients with vulvodynia and impaired vulvar skin, respectively, than in those with vulvar dermatosis and 224.5% and 211.2% higher, respectively, than in those with a normal vulva. This pattern indicates a certain protective role of papillae in conditions with damaged vulvar skin, while the loss of papillae in dermatoses may indicate the collapse of this protective role. Therefore, it is essential to note that the diagnosis of vulvodynia in each case was based on valid recommended criteria, while vulvoscopic findings did not influence the diagnosis.

The covering epithelium of the inner vulvar ring is thinner than the skin of the outer and middle vulvar rings, which enables the condition that occurs in tissue perfusion at the level of the capillary network to be revealed. In addition, spasm of the afferent branch of the capillary network leads to ischemia characterized by a loss of color and pale appearance, which is in contrast to congestion in case of occlusion of the efferent branch of the capillary network with erythema and punctuations. These findings are consistent with those of a previous study that showed that microvascular density did not differ between patients with vulvodynia and controls and that increased perfusion was caused by neurogenic vasodilation [30].

These are also the final reactions in the cascading process of the development of nonspecific lesions in the vulva with an inflammatory process at varying degrees at the histopathological level [8, 9]. An increase in inflammatory cytokines and the concentration of IL-10 and TNF have been described, which directly affect the capillary network condition and cause mucocutaneous hyperalgesia and allodynia [33]. In this process, the activation of Toll-like receptors (TLRs), which are involved in various vascular abnormalities, plays a significant role. Activation of TLRs stimulates signaling cascades as a defense mechanism against invaders and repairs tissue damaged by perfusion disturbances [34].

An exciting finding in this study is the association of epithelial smoothness, loss of relief, and pallor in the urethral sulcus with the diagnosis of vulvodynia. Because the painful urination that accompanies interstitial cystitis is caused by contractions of the detrusor muscle and the vulvoscopic findings correspond to spasm of the afferent arm of the capillary network, questions regarding the role of musculo-fascial spasm of the pelvic muscles in the occurrence of these complaints arise.

In the mid-1990s, pelvic floor muscle hypertonicity was reported as a trigger of overwhelming chronic vulvar pain with well-known comorbidities such as painful bladder syndrome, irritable bowel syndrome, fibromyalgia, and temporomandibular jaw disorder [35–37]. However, physical therapists trained in pelvic dysfunction therapy reported successful restoration of functional tissue and reduced vulvar and sexual pain [35]. This hypothesis deserves further investigation in view of results based on medical evidence.

By describing nonspecific vulvar lesions and their distribution in patients with vulvodynia, this study creates a unique opportunity to introduce vulvoscopy in the differential diagnosis of chronic primary and secondary vulvar discomfort. Therefore, vulvodynia becomes a clinically recognizable disease based on a complex background involving dysfunction of muscles, fascia, blood vessels, and nerve fibers mediated by inflammatory cytokines [38–42]. Furthermore, chronic abnormal stimuli that cause these reactions can slowly dysregulate the spinal cord, interfering with sacral reflexes that regulate sensation and pain [43].

By establishing the characteristic pattern of the type and distribution of nonspecific lesions in patients with vulvodynia, the Budapest criteria for considering vulvodynia as chronic reflex pain syndrome (CRPS) type 1, formerly sympathetic dystrophy, are met [44, 45]. Considering the specific anatomy and histology of the vulva, comparing the findings on the left and right sides is less valuable than comparing changes among the vulvar rings. Therefore, the revised Budapest criteria for diagnosing vulvodynia as CRPS type 1 are proposed, as shown in Table 4. These assumptions create room for new research.

Table 4. A proposal of revised Budapest clinical and diagnostic criteria for vulvodynia as a chronic reflex pain syndrome type I, adjusted for anatomy, histology, and function of the vulva.

Revised Budapest criteria for vulvodynia as CRPS type I	
1) Continuing pain, which is disproportionate to any inciting event	
2) Must report at least one symptom in three of the following categories:	
Sensory:	Reports of hyperesthesia and/or allodynia (chronic vulvar discomfort)
Vasomotor:	Reports of temperature asymmetry and/or skin color changes and/or skin color asymmetry between the three vulvar rings
Sudomotor/edema:	Reports of edema and/or swelling and/or sweating changes and/or sweating asymmetry between the three vulvar rings
Trophic:	Reports of trophic changes (skin and skin adnexa/sebaceous glands)
3) Must display at least one sign at the time of evaluation in two or more of the following categories:	
Sensory:	Evidence of chronic vulvar discomfort/hyperalgesia and/or allodynia (Cotton swab test)
Vasomotor:	Evidence of skin color changes (erythema) and/or skin color asymmetry between the three vulvar rings
Sudomotor/edema:	Evidence of edema and/or swelling and/or swelling asymmetry between the three vulvar rings
Trophic:	Evidence of trophic changes (loss of skin relief/smoothness, ischemia of suburethral sulcus, punctuations, multiplication of sebaceous glands)
4) There is no other diagnosis that better explains the signs and symptoms	

Distribution of nonspecific vulvar lesions

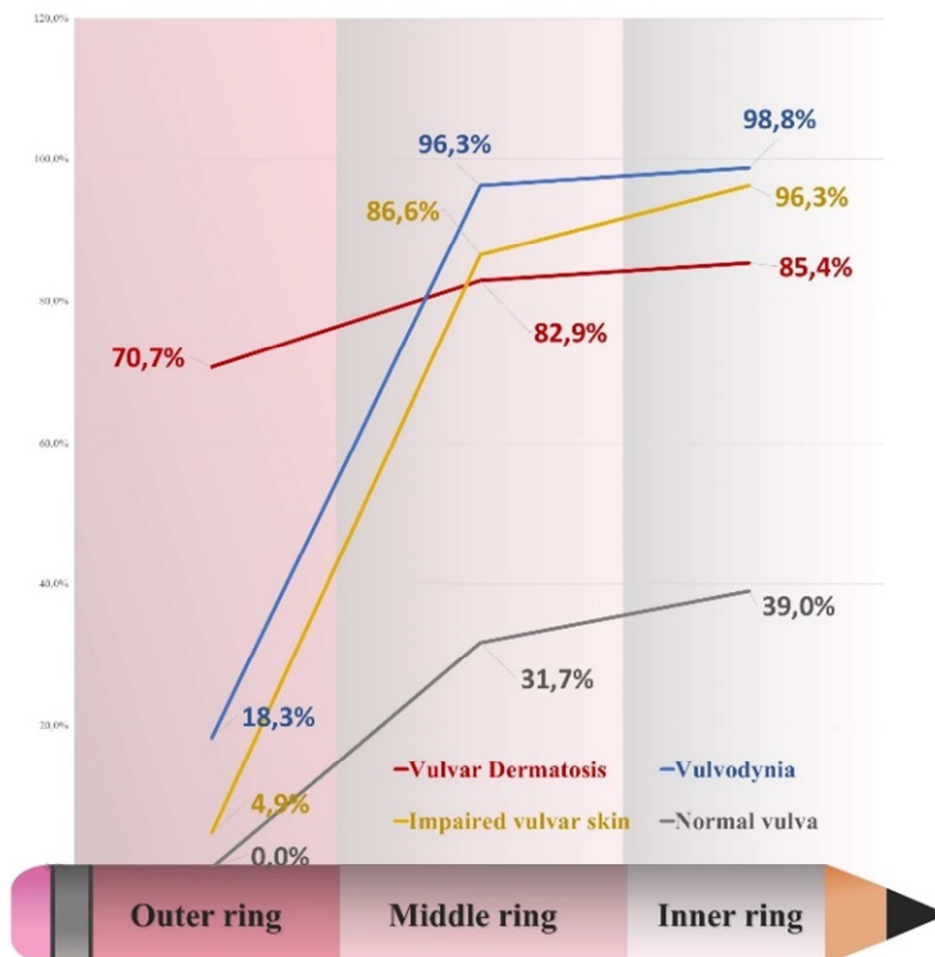


Figure 4. The distribution of nonspecific vulvar lesions associated with the three vulvar rings in patients with primary or secondary chronic vulvar discomfort compared with asymptomatic patients.

The detailed allocation of nonspecific vulvar lesions associated with the three vulvar rings in all patient groups, including asymptomatic patients and those with chronic vulvar discomfort, is presented in Figure 4.

Additional research is needed to verify the importance of the presented results in uncontrolled conditions, intra- and

interobserver variability, the impact of education on the implementation and duration of the examination, and its application in diagnosing and monitoring patients with chronic vulvar discomfort. Recognition and further definition of nonspecific lesions in patients with vulvodynia are crucial for research on the clinical value of vulvoscopy in this area.

5. Conclusion/Recommendations

Evaluating nonspecific vulvar lesions and their distribution according to three vulvar rings in patients with chronic vulvar discomfort demonstrated characteristic and recognizable patterns of appearance in patients with vulvar dermatoses and vulvodynia.

Nonspecific findings in the outer vulvar ring were significantly more common in patients with vulvar dermatosis. The opposite pattern of lesion incidence was observed in the inner vulvar ring, with a significantly higher frequency of nonspecific findings in patients with vulvodynia and impaired vulvar skin. An increased presence of nonspecific lesions in the middle vulvar ring was recorded in all participants, with a clear difference between patients with vulvodynia and vulvar dermatosis.

The inner vulvar ring in patients with vulvodynia showed a peculiar and characteristic profile with significantly more frequent findings of erythema, punctuation, ischemia, and papillae. Therefore, vulvodynia becomes a clinically recognizable disease based on a complex background, including dysfunction of muscles, fascia, blood vessels, and nerve fibers, mediated by inflammatory cytokines, like other CRPS type I. Furthermore, this study proposed revised Budapest criteria for vulvodynia as CRPS type I.

This study creates a unique opportunity to introduce vulvoscopy in the differential diagnosis of chronic primary and secondary vulvar discomfort.

ser destinada como el examen colposcópico de la vulva. [Vulvoscopy should not be intended as colposcopic examination of the vulva.] *AMATGI* 2011; 4: 29-34.

References

- [1] Moyal-Barracco M, Lynch P. 2003 ISSVD terminology and classification vulvodynia: a historical perspective. *J Reprod Med* 2004; 49: 772-7.
- [2] ISSVD Vulvodynia Pattern Questionnaire. Available at: <https://netforum.avectra.com/temp/ClientImages/ISSVD/3ef9c6ea-aac7-4d2b-a37f-058ef9f11a67.pdf> Last accessed May 23, 2015.
- [3] Bornstein J, Goldstein AT, Stockdale CK, Bergeron S, Pukall C, Zolnoun D, et al. 2015 ISSVD, ISSWSH, and IPPS Consensus Terminology and Classification of Persistent Vulvar Pain and Vulvodynia. *J Lower Genit Tract Dis* 2016; 20: 126-30.
- [4] Torres-Cueco R.; Nohales-Alfonso F. Vulvodynia - It Is Time to Accept a New Understanding from a Neurobiological Perspective. *Int J Environ Res Public Health* 2021; 18: 6639. DOI: 10.3390/ijerph18126639.
- [5] International Association for the Study of Pain, Subcommittee on Taxonomy. Classification of chronic pain. Descriptions of chronic pain syndromes and definitions of pain terms. *Pain Supplement* 1986; 3: S1-S226.
- [6] Byrne MA, Walker MM, Leonard J, Pryce D, Taylor-Robinson D. Recognising covert disease in women with chronic vulval symptoms attending an STD clinic: value of detailed examination including colposcopy. *Genitourin Med* 1989; 65: 46-9.
- [7] Micheletti L, Preti M, La Monica F. La vulvosopia, no debe ser destinada como el examen colposcópico de la vulva. [Vulvoscopy should not be intended as colposcopic examination of the vulva.] *AMATGI* 2011; 4: 29-34.
- [8] Audisio T, Zarazaga J, Vainer O. A Classification of Vulvoscopy Findings for Clinical Diagnosis. *J Lower Genit Tract Dis* 1999; 3: 7-18.
- [9] van Beurden M, van der Vange N, de Craen AJM, Tjong-A-Hung SP, ten Kate FJW, ter Schegget J, et al. Normal findings in vulvar examination and vulvoscopy. *J Br Obstet Gynaecol* 1997; 104: 320-4.
- [10] Kesic V. Colposcopy of the vulva, perineum and anal canal. Chapter in Bosze P, Luesley DM. *EACG Course Book on Colposcopy*. Budapest, Primed-X-Press; 2003.
- [11] Harni V, Babic D, Hadzavdic S, Barisic D. Diagnostic Accuracy of the Vulvoscopy Index for Detection of Vulvar Dermatoses (DATRIV Study, Part 1). *Journal of Gynecology and Obstetrics* 2022; Vol. 10, No. 1, 39-47. DOI: 10.11648/jgo.20221001.16.
- [12] Harni V, Babic D, Hadzavdic S, Barisic D. Clinical Value of the N-S-P Scheme for Detection of Vulvar Dermatoses (DATRIV Study, Part 2). *Journal of Gynecology and Obstetrics* 2022; Vol. 10, No. 3, 159-166. DOI: 10.11648/jgo.20221003.11.
- [13] Friedrich EG Jr. Vulvar vestibulitis syndrome. *J Reprod Med* 1987; 32: 110-4.
- [14] Haefner H, Collins M, Davis GD, Edwards L, Foster D, Hartmann E, et al. The Vulvodynia Guideline. *J Lower Genit Tract Dis* 2005; 9: 40-51.
- [15] Stockdale CK, Lawson HW. 2013 Vulvodynia Guideline Update. *J Lower Genit Tract Dis* 2014; 18: 93-100.
- [16] Bornstein J, Sideri M, Tatti S, Walker P, Prendiwill W, Haefner HK. 2011 Terminology of the Vulva of the International Federation for Cervical Pathology and Colposcopy. *J Lower Genit Tract Dis* 2012; 16: 290-5.
- [17] Reid R, Greenberg MD, Daoud Y, Husain M, Selvaggi S, Wilkinson E. Colposcopic findings in women with vulvar pain syndromes. A preliminary report. *J Reprod Med* 1988; 33: 523-532.
- [18] Harni V, Babic D, Barisic D. "Three Rings Vulvoscopy" – A New Approach to the Vulva. *Gynaecol Perinatol* 2015; 24: 37-45. Available at: <https://www.poliklinika-harni.hr/images/publikacije/Harni-V-Three-Rings-Vulvoscopy-Gyn-Per-2015.pdf>
- [19] Micheletti L, Preti M, Bogliatto F and Lynch P. Vulvology A Proposal for a Multidisciplinary Subspecialty. *J Reprod Med* 2002; 47 (9): 715-7. Available at: <http://hdl.handle.net/2318/40198>
- [20] Murphy R. Training in the diagnosis and management of vulvovaginal diseases. *J Reprod Med* 2007; 52 (2): 87-92.
- [21] Venkatesan A, Farsani T, O'Sullivan P, Berger T. Identifying competencies in vulvar disorder management for medical students and residents: a survey of US vulvar disorder experts. *J Low Genit Tract Dis* 2012; 16 (4): 398-402. DOI: 10.1097/LGT.0b013e318245152b.
- [22] ISSVD - the World for Vulvovaginal Education and Research. <https://www.issvd.org/>

- [23] Edwards C, Dogra N, Antanrajakumar A, Saeangapani A, Selk A. Vulvovaginal Disease Education in Canadian and American Gynecology Residency Programs: A Survey of Program Directors. *J Low Genit Tract Dis* 2018; 22 (3): 242-250. DOI: 10.1097/LGT.0000000000000390.
- [24] Marinoff SC, Turner ML. Vulvar vestibulitis syndrome. *Dermatol Clin* 1992; 10 (2): 435-44.
- [25] Meets, JF. Vulvodynia and vulvar vestibulitis: challenges in diagnosis and management. *Am Fam Physician* 1999; 59 (6): 1547-56, 1561-2.
- [26] Reed B. Vulvodynia: Diagnosis and Management. *Am Fam Physician* 2006; 73 (7): 1231-8.
- [27] Gardella C. Vulvar vestibulitis syndrome. *Curr Infect Dis Rep* 2006; 8 (6): 473-80. DOI: 10.1007/s11908-006-0022-8.
- [28] Michlewitz H, Kennison RD, Turksoy RN, Fertitta LC. Vulvar vestibulitis--subgroup with Bartholin gland duct inflammation. *Obstet Gynecol* 1989; 73 (3 Pt 1): 410-3.
- [29] Petersen E. Frauen mit chronischen Vulvabeschwerden. *Frauenarzt* 2012; 53 (3): 246-52. Available at: <https://www.frauenarzt.de/index.php/heftarchiv/53-jahrgang-2012/frauenarzt-3-12/468-fa-2012-3-fort-frauen-mit-chronischen-vulvabeschwerden/file>
- [30] Bohm-Starke N, Hilliges M, Blomgren B, Falconer C, Rylander E. Increased blood flow and erythema in the posterior vestibular mucosa in vulvar vestibulitis (1). *Obstet Gynecol* 2001; 98 (6): 1067-74. DOI: 10.1016/s0029-7844(01)01578-2.
- [31] Chan NP, Zimarowski MJ. Vulvar dermatoses: a histopathologic review and classification of 18 cases. *J Cutan Pathol* 2015; 42: 510-518. DOI: 10.1111/cup.12541.
- [32] Simpson RC, Thomas KS, Leighton P, Murphy R. Diagnostic criteria for erosive lichen planus affecting the vulva: an international electronic-Delphi consensus exercise. *British Journal of Dermatology* 2013; 169: 337-343.
- [33] Foster DC, Hasdey JD. Elevated Tissue Levels of Interleukin-1/3 and Tumor Necrosis Factor- α in Vulvar Vestibulitis. *Obstet Gynecol* 1997; 89: 291-6.
- [34] Wang Y, Song E, Bai B, Vanhoutte PM. Toll-like receptors mediating vascular malfunction: lessons from receptor subtypes. *Pharm & Therap* 2016; 18: 91-100. DOI: 10.1016/j.pharmthera.2015.12.005.
- [35] Hartmann D, Sarton J. Chronic pelvic floor dysfunction, Best Practice & Research *Clinical Obstetrics and Gynaecology* 2014. DOI: 10.1016/j.bpobgyn.2014.07.008.
- [36] Gentilcore-Saulnier E, McLean L, Goldfinger C, et al. Pelvic floor muscle assessment outcomes in women with and without provoked vestibulodynia and the impact of a physical therapy program. *J Sex Med* 2010; 7: 1003e22.
- [37] Kennedy CM, Nygaard IE, Saftlas A, Burns LT, Torner JC, Galask RP. Vulvar disease: A pelvic floor pain disorder? *Am J Obstet Gynecol* 2005; 192: 1829-35.
- [38] Stewart EG, Berger BM. Parallel pathologies? Vulvar vestibulitis and interstitial cystitis. *J Reprod Med* 1997; 42: 131-4.
- [39] de Jong MJ, van Lunsen RHW, Robertson EA, Stam LNE, Lammes FB. Focal vulvitis: a psychosexual problem for which surgery is not the answer. *J Psychosom Obstet Gynecol* 1995; 16: 85-91.
- [40] Paavonen J. Diagnosis and treatment of vulvodynia. *Ann Med* 1995; 27: 175-81.
- [41] Foster DC, Robinson JC, Davis KM. Urethral pressure variation in women with vulvar vestibulitis syndrome. *Am J Obstet Gynecol* 1993; 169: 107-12.
- [42] Westrom LV, Willen R. Vestibular nerve fiber proliferation in vulvar vestibulitis syndrome. *Obstet Gynecol* 1998; 91: 572-6.
- [43] Comiter C. Sacral neuromodulation for the symptomatic treatment of refractory interstitial cystitis: a prospective study. *J Urol* 2003; 169: 1369-73.
- [44] Casale R, Elam M. Normal sympathetic nerve activity in a reflex sympathetic dystrophy with marked skin vasoconstriction. *Journal of the Autonomic Nervous System* 1992; (41): 215-220.
- [45] Harden RN, Bruehl, Perez RSGM, Birklein F, Marinus J, Maihofner C. et al. Validation of proposed diagnostic criteria (the "Budapest Criteria") for Complex Regional Pain Syndrome. *Pain* 2010; 150 (2): 268-274. DOI: 10.1016/j.pain.2010.04.030.