

Case Report

Post Thermal Sciatic Nerve Injury Successfully Repaired with a Sural Nerve Graft: Case Report

Nangole Wanjala Ferdinand¹, Ochieng Sephania Raduma²

¹Department of Surgery, University of Nairobi, Nairobi, Kenya

²Defense Forces Memorial Hospital, Nairobi, Kenya

Email address:

fwanjala@uonbi.ac.ke (N. W. Ferdinand), drraduma@gmail.com (O. S. Raduma)

To cite this article:

Nangole Wanjala Ferdinand, Ochieng Sephania Raduma. Post Thermal Sciatic Nerve Injury Successfully Repaired with a Sural Nerve Graft: Case Report. *Journal of Surgery*. Vol. 7, No. 5, 2019, pp. 119-122. doi: 10.11648/j.js.20190705.11

Received: February 28, 2019; **Accepted:** July 8, 2019; **Published:** August 6, 2019

Abstract: Loss of the sciatic nerve may result in paralysis and sensory loss of the leg. Among indications for lower limb amputation is blunt trauma to the nerve that is feared to have no chances of recovery. Injuries of thermal in nature are thought to have an extensive damage far from the site of injury and are thus unlikely to recover. The injured nerve is likely to heal by fibrosis and scarring making it difficult for any axons to go through it. The only hope for such recovery is removal of all injured sections followed by the nerve repair with a nerve graft or nerve transfer. With advances in microsurgery more and more injured nerves that were otherwise considered unsalvageable are now routinely reconstructed with relatively good outcomes. A good proportion of this are nerve injuries of the upper limbs such brachial plexus, median, ulnar and radial nerve injuries. Compared to the upper limb nerve injuries there is little data on the outcomes of lower limb nerve injuries. The tendency towards amputation of the lower limb following blunt trauma to the sciatic nerve is much higher than the upper limb. We present a case of post traumatic thermal sciatic nerve injury that was repaired with a sural nerve graft with good outcomes.

Keywords: Sciatic Nerve Injury, Post Thermal, Repair

1. Introduction

Injury to the sciatic nerve is potentially fatal and could lead to the loss of the extremity. Majority of the injuries rarely occurs in isolation. Appropriate reconstruction of such wounds requires repair of all structures damaged during the injury. Vascular structures if injured must be repaired urgently before the limb gets irreversible ischaemia. Soft tissue coverage may be by direct wound closure or local flaps as the case may demand. We present a case of a patient who presented to us with extensive injury to the right limb at the work place who was successfully reconstructed.

2. Case Presentation

A twenty six year old factory worker sustained thermal injury to the right lower limb secondary to a hot metal rod. The rod was about 10 cm in diameter. After initial resuscitation, and wound bed preparation the patient's defect

was reconstructed in a one stage surgical procedure. At surgery he was found to have a wound involving the posterior aspect of the knee and lower thigh of about 15cm by 20cm in dimensions (figure 1).

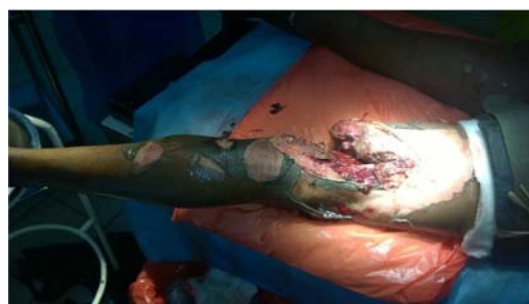

Figure 1. Patient with post thermal soft tissue loss and sciatic nerve injury.

The injury to the nerve was from the distal sciatic nerve to the proximal tibia and common peroneal nerve totaling about 12 centimeters in length. (figure 2).

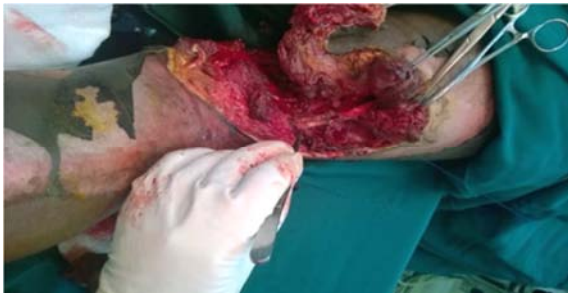

Figure 2. Wound post surgical debridement, sciatic nerve defect about 12 centimetres.

A Sural nerve graft of about 30 cm in length was harvested from the contralateral leg. [figure 3]. The nerve was cut into two parts with one coapted into the lateral aspect of the sciatic nerve and the common peroneal nerve and the other the medial aspect of the sciatic nerve and the tibial nerve. Medial gastrocnemius muscle was raised as a pedicle flap and utilized to cover the neurovascular structures. [figure 4]. The muscle and the burnt areas were grafted at the same sitting with good graft take [figure 5]. At six months of follow up the wound had fully healed and no contractures were noted. [figure 6]. Post operatively the knee was splint with a knee cast. The Patient was commenced on physiotherapy two weeks after surgery. Nerve recovery was assessed by the progression of the Tinel sign, motor and sensory response. At six months of follow up the patient had knee flexion followed by recovery of the foot drop after one and a half years of follow up. [figure 7]. Sensory recovery over the heel and dorsum of the foot was noted at about one year of follow up.

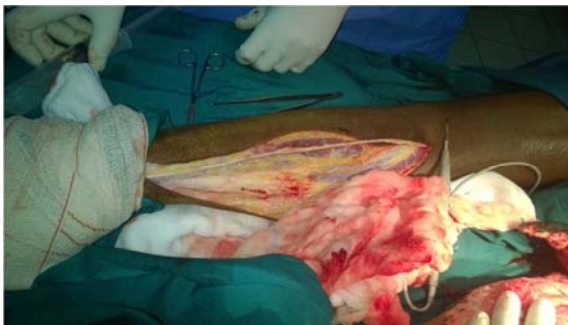

Figure 3. Sural nerve graft identified and being harvested from the contralateral leg.

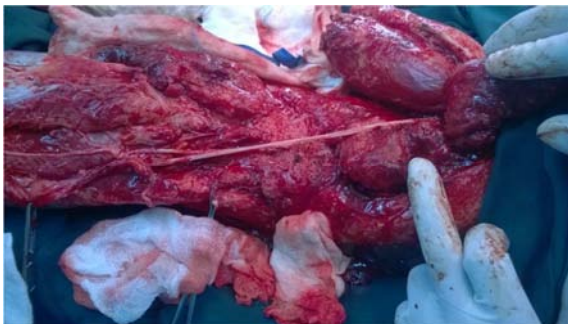


Figure 4. Sural nerve graft used to establish continuity between the sciatic nerve and the tibial and common peroneal nerves.

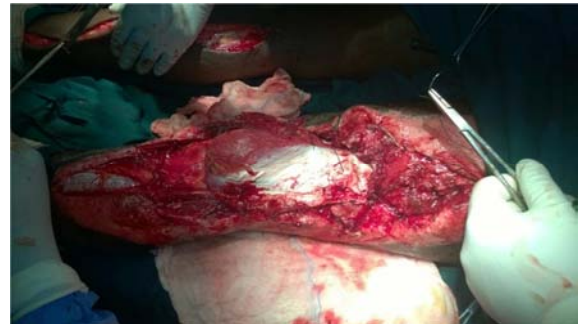

Figure 5. Soft tissue coverage over the repaired Nerve.

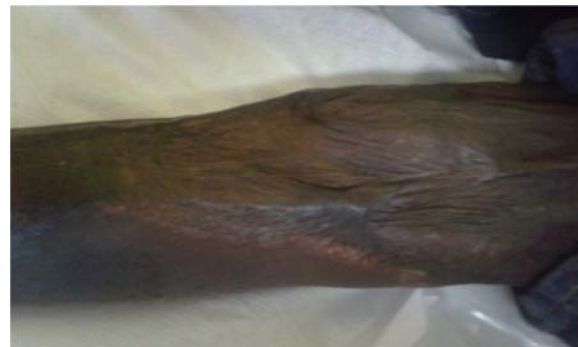

Figure 6. Wounds fully healed at six months of follow up.

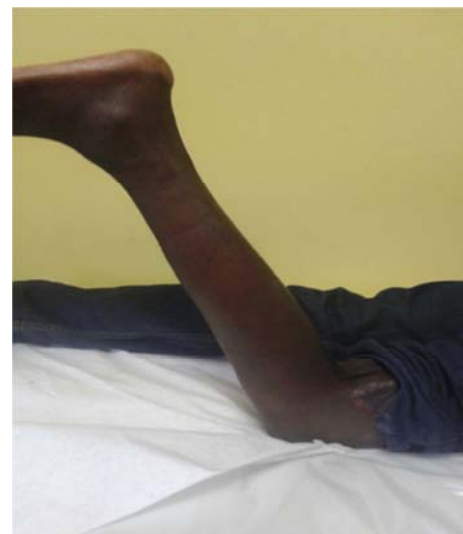

Figure 7. Patient able to flex the knee against gravity at six months of follow up.

3. Discussion

Incidences of sciatic nerve injuries are approximately two percent of all peripheral nerve injuries [1], the incidence of periphery nerve injuries constitute about 1.8 percent of all patients with traumatic injuries. [2]. The aetiology of majority of sciatic nerve injuries are trauma related with either motor vehicle accident or gunshot injuries contributing to bigger proportion. [3, 4] Iatrogenic injuries including laser related injuries have also been documented to do contribute to these injuries. [5] Repairs of the lower limb nerve injury are less common compared to the upper limb nerve injuries.

The outcomes are also considered inferior [6, 7]. Unsuccessful repair may result in an insensate and paralyzed limb that may be unpleasant to the patient and hence necessitating amputation. However with refinement of microsurgical techniques sciatic nerve injuries can be repaired with good surgical outcomes like in our patient and thus obviating the need for amputation.

Different authors have reported inconsistent outcomes with sciatic nerve repairs. Trumble in a retrospective review of patients operated on in the 80s and 90s showed only one patient with protective sensations out of thirteen patients reviewed [7]. Aydin in a series of 11 patients, found seven with protective sensation of the foot and at least 50 percent with good motor outcome [6]. The reasons for this inconsistent results could be due to different anatomical location of the lesions, the length of the nerve defect, the surgical experience of the surgeon especially in microsurgical techniques and the nature of the injury. Proximal injuries of the nerve tend to have worse outcomes as compared to distal nerve injuries. [8, 9] Nerve injuries that could be repaired primarily with no need for nerve grafts tend to do better than those that require nerve grafts. [8-10] Injuries of the tibial branch of the sciatic nerve tend to recover better than those involving the common peroneal nerve. [8-13] Children tend to recover better than adults probably as a result of the plasticity in children.

Our patient sustained injuries secondary to a hot rod at the place of work. The extent of the injury resulted in destruction of the skin subcutaneous tissues and the surrounding muscles. The sciatic nerve was extensively damaged resulting in a nerve defect of about 12 cm in length. The challenges in reconstructing this patient included ability to provide sufficient soft tissue coverage as well ensuring that the nerve was appropriately repaired so as to allow for a tension free repair and healthy nerve ends that could allow for regrowth of the neurons. (Some authors do consider absence of well vascularised soft tissue patient like in our an indication of amputation). The options for the nerve repair was either to use a nerve graft or a vascularised nerve. [9-12, 14] The nerve graft is technically less challenging but has been shown to have suboptimal outcomes as compared to the vascularised nerve flaps. [8] The vascularised nerve are however more technically demanding requiring longer operative time. The soft tissue loss was appropriately repaired with local muscle flaps and skin grafts. The muscle flaps provided adequate vascularity for the nerve graft to take and hence allow for the regrowth of the axons. Other options for the soft tissue coverage would have been a free flap.

The order of functional recovery for the patient was motor followed by sensory. Muscles innervated by the tibial nerve showed recovery first followed by those supplied by the common peroneal nerve. This has also been documented by other authors. [2-4] The reasons for this could be due to the proximities of these muscles to the nerves. Sensory recovery was last. In spite of the delayed sensory recovery our patient did not experience any wounds or ulcerations as would have been expected with the insensate extremity. After full nerve recovery at about one year of follow up he had attained good

protective sensation all the way to the plantar aspect of the foot.

4. Conclusion

Patient with extensive injuries of the sciatic nerve accompanied by soft tissue loss should be given a chance of reconstruction. The options for reconstruction should be guided by the reconstruction principles of both the nerve and soft tissue loss. In such wounds one must be able to provide adequate vascularised soft tissue coverage as well as reconstruct the nerve defect with a nerve conduit. With meticulous reconstruction and appropriate post operative follow up good functional outcome can be attained and thus avoid amputations.

Conflict of Interest

All the Authors do not have any possible conflict of interest.

References

- [1] Asplund M, Nilsson M, Jacobsson A et al, Incidence of traumatic peripheral nerve injuries and amputations in Sweden between 1998 and 2006. *Neuroepidemiology*. 2009; 7: 217–228. doi: 10.1159/000197900. [PubMed] [Cross Ref].
- [2] Torge Huckhagel Jakob Nüchtern², Jan Regelsberger¹ Nerve trauma of the lower extremity: evaluation of 60,422 leg injured patients from the Trauma Register DGU® between 2002 and 2015 *Scandinavian Journal of Trauma, Resuscitation and Emergency Medicine* 2018, 26: 40 <https://doi.org/10.1186/s13049-018-0502-5>.
- [3] Georg Reith, Rolf Lefering, Arasch Wafaisade, Kai O. Hensel Injury pattern, outcome and characteristics of severely injured pedestrian Scand J Trauma Resusc Emerg Med. 2015; 23: 56. Published online 2015 Aug 5. doi: 10.1186/s13049-015-0137-8.
- [4] Immerman I, Price AE, Alfonso I, Grossman JAI. Lower extremity nerve trauma. *Bull Hosp Joint Dis*. 2014; 72 (1): 43–52. Google Scholar.
- [5] Shahid, K. R., Dellon, A. L., Amrami, K. K., & Spinner, R. J. (2015). Sciatic and peroneal nerve injuries after endovascular ablation of lower extremity varicosities: Case reports and review of the literature. *Annals of Plastic Surgery*, 74 (1), 64-68. <https://doi.org/10.1097/SAP.0000000000000193>.
- [6] Aydin A1, Ozkan T, Aydin HU, Topalan M, Erer M, Ozkan S, The results of surgical repair of sciatic nerve injuries. *Acta Orthop Traumatol Turc*. 2010; 44 (1): 48-53. doi: 10.3944/AOTT.2010.2172.
- [7] Trumble TE1, Vanderhooft E, Khan U, Sural nerve grafting for lower extremity nerve injuries. *J Orthop Trauma*. 1995 Apr; 9 (2): 158-63.
- [8] Kim DH, Murovic JA, Tiel R, Kline DG. Management and outcomes in 353 surgically treated sciatic nerve lesions. *J Neurosurg*. 2004; 7: 8–17. doi: 10.3171/jns.2004.101.1.0008. [PubMed] [CrossRef].

- [9] Korompilias AV1, Payatakes AH, Beris AE, Sciatic and peroneal nerve injuries Neurosurgery. 2009 Oct; 65 (4 Suppl): A18-23. doi: 10.1227/01. NEU. 0000339123.74649. BE.
- [10] Amanda Maripuu, 1Anders Björkman, 1Isabella M Björkman-Burtscher Reconstruction of sciatic nerve after traumatic injury in humans - factors influencing outcome as related to neurobiological knowledge from animal researchJ Brachial Plex Peripher Nerve Inj. 2012; 7: 7. Published online 2012 Oct 10. doi: 10.1186/1749-7221-7-7 PMCID: PMC35400248.
- [11] Kline DG, Kim D, Midha R, Harsh C, Tiel R. Management and results of sciatic nerve injuries: a 24-year experience. J Neurosurg. 1998; 7: 13–23. doi: 10.3171/jns. 1998.89.1.0013. [PubMed] [Cross Ref].
- [12] Vayvada H, Demirdöver C, Menderes A, Yilmaz M, Karaca C. The functional results of acute nerve grafting in traumatic sciatic nerve injuries. Turk J Trauma Emerg Surg. 2013; 19 (2): 109–14.15. Kim DH, Cho Y, Ryu S, Tiel RL, Kline DG. Surgical management and results of 135 tibial nerve lesions at the Louisiana State University health sciences center. Neurosurgery. 2003; 53: 1114–25. View ArticlePubMedGoogle Scholar.
- [13] Kim DH, Murovic JA, Tiel RL, Kline DG. Management and outcomes in 318 operative common peroneal nerve lesions at the Louisiana State University health sciences center. Neurosurgery. 2004; 54: 1421–9. View ArticlePubMedGoogle Scholar.
- [14] Terzis JK, Kostopoulos VK, Vascularized nerve grafts for lower extremity nerve reconstruction. Ann Plast Surg. 2010 Feb; 64 (2): 169-76.
- [15] Guangyao Liu, 1Rui Jiang, 1 and Yan Jin, M. D. 2 Sciatic nerve injury repair: a visualized analysis of research fronts and development trends Neural Regen Res. 2014 Sep 15; 9 (18): 1716–1722.