



# A 2-year Review of Wound Outcome Following Primary Skin Closure After Laparotomy for Typhoid Ileal Perforation in Bida, Nigeria

Adekunle Adedapo Abiodun<sup>\*</sup>, Alexander Gomna, Emmanuel Adewale Eletta,  
Michael Adewale Ayeni, Adedeji Adekanye, Taofeeq Abdulrahman, Sunday Akintunde Okinbaloye

Department of Surgery, Federal Medical Centre, Bida, Nigeria

## Email address:

abiodunkunle2012@hotmail.com (A. A. Abiodun)

<sup>\*</sup>Corresponding author

## To cite this article:

Adekunle Adedapo Abiodun, Alexander Gomna, Emmanuel Adewale Eletta, Michael Adewale Ayeni, Adedeji Adekanye, Taofeeq Abdulrahman, Sunday Akintunde Okinbaloye. A 2-year Review of Wound Outcome Following Primary Skin Closure After Laparotomy for Typhoid Ileal Perforation in Bida, Nigeria. *Journal of Surgery*. Vol. 8, No. 4, 2020, pp. 132-135. doi: 10.11648/j.js.20200804.16

**Received:** June 17, 2020; **Accepted:** July 20, 2020; **Published:** August 4, 2020

---

**Abstract:** Introduction: Laparotomy wound for typhoid ileal perforation is a dirty wound and is usually associated with wound complications and prolonged hospital stay. Delayed primary wound closure which for long has been the most common practice after laparotomy for typhoid peritonitis is now considered to be of little significance in preventing surgical site infection (SSI). We aimed to document the incidence, severity and management of wound complications when primary closure of abdominal wounds was performed following laparotomy for typhoid ileal perforation. Patients and Methods: This was a retrospective study of all patients who had primary abdominal wound closure following laparotomy for typhoid ileal perforation in Federal Medical Centre, Bida from January 2017 to December 2018. Results: There were 71 patients with the age ranges from 2 to 41 years and their median age was 15 years who had laparotomy for typhoid ileal perforation during the study period. All 71 patients had primary closure of their abdominal wounds, however two of them died within 72 hours of operation and were excluded from the study. There were males 38 (55.1%) and females 31 (44.9%) with a male to female ratio of 1.2:1. There was primary wound healing in 23 (33.3%) patients while 44 (63.8%) of them developed incisional surgical site infections (SSI) and 2 (2.9%) developed organ space SSI. Of the 44 patients that had incisional SSI, 33 (75.0%) were superficial and 11 (25.0%) were deep. Other complications noted from the study were faecal fistulae 3 (4.3%) and incisional hernia (4.3%). Conclusion: Though a high incidence of wound morbidity is not unexpected in situation of primary closure of laparotomy wound for bacteria peritonitis, an aggressive wound management may help to reduce the incidence and severity of wound complications in such situations.

**Keywords:** Primary Wound Closure, Wound Complication, Ileal Perforation

---

## 1. Introduction

Wound following operation for typhoid ileal perforation is considered a dirty surgical wound and it is associated with a high rate of wound infection [1-3]. With most patients now surviving operation for typhoid ileal perforation, focus is gradually shifting to how to reduce the high morbidity rate and prolonged hospital stay which greatly increase cost of medical care [4]. Wound complication is one of the most challenging problem faced by the attending surgeon in the post-operative period. Wound infection is associated with

considerable burdens on the patient by increasing the cost of care, prolonged hospital stay, loss of patients' productivity time, patient dissatisfaction with care and reduced quality of life [5-8].

The method of skin closure is an important factor that influences the outcome of a surgical wound [9]. Wound closure after laparotomy for typhoid ileal perforation can either be primary or delayed primary closure [10]. To date, there is constant debate in literature on the optimal method of closure of this class of wounds. The results of comparative studies showed that delayed primary closure of wounds had

no advantage over primary closure in term of surgical site infection (SSI) rate [11, 12].

In this study, we aim to document the incidence, pattern and management of wound complications following primary closure of laparotomy wound for typhoid ileal perforation in Federal Medical Centre, Bida, Nigeria.

## 2. Patients and Methods

We retrospectively reviewed the records of patients who had operation for typhoid intestinal perforation at Federal Medical Centre (FMC), Bida between January 2017 and December 2018. Federal Medical Centre Bida is a tertiary hospital, in Niger state, Nigeria with a bed capacity of 200. The patients' clinical records were retrieved from the paediatrics and adult emergency unit, surgical outpatient clinics and wards.

All relevant information were obtained from patients' record; these included the socio-demographic characteristics, admission–operation time, operative findings, types of operation, wound outcome following surgery and its management for analysis.

Two out of the 71 patients died within the first 72 hours of surgery before evidence of SSI could be seen and so they were excluded from the study. All the patients were resuscitated and had adequate antibiotics pre-operatively, intra-operatively and post-operatively.

Laparotomy was performed on all 69 patients through either transverse subumbilical incision in small children or midline incision in older children and adult patients.

The procedure (s) performed on each patient was based on the operative findings. The peritoneal cavity was lavaged with warm normal saline until clear effluent was obtained and mopped. The abdominal wound was closed en mass closure of the peritoneum and linea alba with using a simple continuous technique with appropriate nylon sutures. The subcutaneous tissue and skin were then closed primarily in all cases with appropriate sutures inserted at intervals.

The wounds were routinely inspected from the third postoperative days for evidence of surgical site infection. A wound infection was deemed to have occurred when there was cellulitis, purulent discharge along the wound or pus collection in the peritoneal cavity.

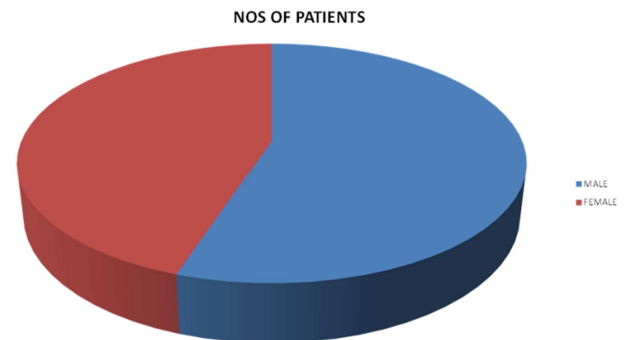
Once there was evidence of infection, sutures around the infected sites were removed to allow for free egress of the wound discharge and wound dressing was commenced. The data was analysis with Statistical Package for Social Sciences (SPSS) version 25.0 for windows.

## 3. Result

There were 71 patients had laparotomy for typhoid ileal perforation over the 2 year period. All had their wounds closed primarily. None of the patients had anterior abdominal wall oedema prior to surgical intervention. Their ages ranged from 2–41 years (median=15 years).

Two patients died within 72 hours of surgical intervention

before SSI could be established, and were excluded from the study. Of the remaining 69 cases, there were 38 males and 31 females (M:F=1.2:1) [figure 1]. All the patients had established symptoms and signs of typhoid ileal perforation. The majority (38.0%) of the patients had laparotomy performed between 12–24 hours of admission.



**Figure 1.** The sex distribution of patients in the study.

Single perforation 49 (71.0%) was the predominant finding in most of the patients. The distance between most distal perforation site to the ileo-caecal junction ranged between 1cm and 100 cm and most perforations were found between 11 and 20cm from the ileo-caecal junction. The size of the perforations ranged from 0.4cm to 12cm with median size of 1cm. The mean volume of faeculent material drained was 897.9 mL (range 100–3000 mL). The procedures done were as shown in table 2, with the commonest procedure being simple closure of perforations in 53 (76.8%) patients.

**Table 1.** OPERATIVE FINDINGS IN THE PATIENTS.

Number of perforations	Number of patients (69)	% (100)
1	49	71.0
2	17	24.6
3	1	1.4
4	1	1.4
5 and above	1	1.4

Size of perforations (cm)	Number of perforations (97)	% (100)
0.1 – 2.0	85	87.6
2.1 – 4.0	8	8.2
> 4.0	4	4.1

Most distal perforation from ICJ (cm)	Number of patients (69)	% (100)
< 10cm	16	23.2
11 – 20	23	33.3
21 – 30	14	20.3
31 – 40	13	18.8
41 – 50	6	8.7
>50	3	4.3

Estimated volume of contaminants (L)	Number of patients (69)	% (100)
0.1 – 1.0	37	53.6
1.1 – 2.0	12	17.4
2.1 – 3.0	9	13.0
3.1 – 4.0	3	4.35
>4.0	4	5.8
Missing value	4	5.8

**Table 2. PROCEDURE DONE IN THE PATIENTS.**

Procedure	Number (69)	% (100)
Simple closure	53	76.8
Resection and anastomosis	5	7.2
Resection with ileostomy	6	8.7
Right hemicolectomy	5	7.2

In all, there was primary wound healing in 23 (33.3%) patients, while 46 (66.7%) patients developed surgical site infections. The SSI rate was 66.7% of which 44 (63.8%) of them developed incisional SSI and 2 (4.3%) developed organ space SSI. Of the 44 patients that developed incisional SSI, 33 (75.0%) were superficial and 11 (25.0%) were deep. Concerning post-operative management of the wound,

removal of appropriate stitches and daily dressing were instituted in 19 of the 33 (57.6%) with superficial SSI to achieve complete wound healing/closure while the remaining 14 (42.4%) had secondary wound closure after clean wound was achieved by wound dressing. For deep SSI, 6 of the 13 had burst abdomen and they eventually had tension suturing applied while the remaining 7 patients had secondary wound closure after the wound were adjudged cleaned. Other wound complications noted from the study were intraabdominal abscess 2 (2.9%), enterocutaneous fistulas 3 (4.3%) and incisional hernia 3 (4.3%). The patients with intraabdominal abscess and enterocutaneous fistulae had reexploration while those with incisional hernia were planned for mesh repair.

**Table 3. WOUND OUTCOME AND MANAGEMENT.**

Complications	Number of patients (46)	%	Management
Superficial SSI alone	19	41.3	Dressing only
Superficial SSI with partial wound dehiscence	14	30.4	Dressing+Secondary closure
Deep SSI alone	7	15.2	Dressing+Secondary closure
Deep SSI complete wound dehiscence	4	8.7	Tension suturing
Organ space/intraabdominal collection	2	4.3	Re-exploration

## 4. Discussion

Typhoid ileal perforation is one of the common abdominal surgical emergencies seen in our centre. Primary wound closure following laparotomy for typhoid ileal perforation is usually our choice method of closure in our centre except where there are contraindications like abdominal wall oedema. The study was undertaken to look at the wound outcome of primary skin closure following laparotomy for typhoid ileal perforation.

Delayed primary closure of dirty wound usually done between three to five days after operation, has been the accepted practice over many years [13]. The delay allows the wound to gain resistance to infection by decreasing the risk of bacterial colonization. This is achieved by allowing free egress of wound exudates [3]. However, leaving this wound for 3 to 5 days while waiting for delayed primary closure is usually frightening and causes anxiety in patients and their caregivers [9]. This has been one of the reasons why many surgeons practice primary closure of such wounds [7].

With most patients now surviving surgery for typhoid ileal perforation, the focus is gradually shifting from mortality to the high morbidity rate with the attendant prolonged hospital stay which have the over-burdened health system and increased cost of medical expenditure of patients [6]. Incisional surgical site infection (SSI) rate of 64.8% was a significant morbidity recorded in this study. Ugochukwu et al and Chalya et al had similar results from their studies which reported the SSI rate of 63.6% and 55.5% respectively [7, 9]. This is not unexpected because operative wound from typhoid ileal perforation is usually considered dirty wound which carries high wound infection rate. The wound complications recorded from this study followed similar pattern of what has been previously reported for dirty wounds [1, 9, 11, 14]. Some studies have justified promotion

of primary wound closure because the post-operative wound complications of the two methods were similar. In a retrospective series by Adesunkanmi and Ajao, it was found that delayed primary closure has no extra benefit in typhoid ileal perforation when compared to primary closure. Also Agrawal et al., concluded from his randomized clinical trial that the time of wound closure of dirty abdominal incisions has no significant impact on incidence of wound infection and wound dehiscence [6, 9]. However, in a randomized control study by Duttaroy et al., it was revealed that delayed primary closure of dirty abdominal incisions which included patients with typhoid ileal perforation was associated with significant reduction in rates of wound infection and wound dehiscence compared to primary closure [15].

Most of the patients in our series had their wound complications managed by dressing and secondary closure with only little additional financial cost on the patients' care.

## 5. Conclusion

The infectious morbidity following primary closure of laparotomy wound for typhoid ileal perforation is still high but with early surgical intervention and aggressive wound care, the severity of wound complication can be reduced. Most of the complications required no further operative intervention and a few required minor side-ward procedures to achieve complete wound healing. It is recommended that primary wound closure should be practiced in the absence of obvious contraindication such as abdominal wall oedema.

## References

- [1] Kache SA, Mshelbwala PM, Ameh EA. Outcome of primary closure of abdominal wounds following laparotomy for peritonitis in children Afr J Paediatr Surg. 2016 Oct-Dec; 13 (4): 185–188.

- [2] Cruse PJ, Foord R. The epidemiology of wound infection. A 10-year prospective study of 62,939 wounds. *Surg Clin North Am.* 1980; 60: 27–40.
- [3] Usang UE, Sowande OA, Ademuyiwa AO, Bakare TI, Adejuyigbe O. Outcome of primary closure of abdominal wounds following typhoid perforation in children in Ile-Ife, Nigeria. *Afr J Paediatr Surg.* 2009; 6: 31–4.
- [4] Ukwenya AY, Ahmed A, Garba ES Progress in management of typhoid perforation. *Annals of African Medicine* Vol. 10, No. 4; 2011. 259-265.
- [5] Mueller TC, Nitsche U, Victoria Kehl V, Schirren R, Schossow B, Goess R, Friess H, Reim D. Intraoperative wound irrigation to prevent surgical site infection after laparotomy (IOWISI): study protocol for a randomized controlled trial. *Orphanet journal of rare disease.* (2017).
- [6] Ghafouri, H. B., Zavareh, M., Jalili, F., Cheraghi, S. Is 1% povidone-iodine solution superior to normal saline for simple traumatic wound irrigation? *Wound Medicine* 15, 1-5, (2016).
- [7] Bigliardi PL, Alasagoff SAL, El-Kafrawi HY, Pyon JK, Wa CTC, Villa MA. Povidone iodine in wound healing: A review of current concepts and practices. *International Journal of Surgery.* 44, 260-268 (2017).
- [8] Norman G, Atkinson RA., Smith TA, Rowlands C, Rithalia AD, Crosbie EJ, Dumville JC. In *Cochrane systematic Review* (2017.).
- [9] Agrawal V, Joshi MK, Gupta AK, Jain BK. Wound Outcome Following Primary and Delayed Primary Skin Closure Techniques After Laparotomy for Non-Traumatic Ileal Perforation: a Randomized Clinical Trial *Indian J Surg.* 2017 Apr; 79 (2): 124–130. Published online 2016 Jan 15.
- [10] Idris OL, Idris OJ, Kolawole OA, Adejumbi MO, Adegoke AA, Oseni OG, Agbakwuru EA. Comparative Study of Wound Complications following Laparotomy for Typhoid Intestinal Perforation: Primary versus Delayed Primary Closure? A Prospective Randomized trial. *IOSR Journal of Dental and Medical Sciences (IOSR-JDMS)* e-ISSN: 2279-0853, p-ISSN: 2279-0861. Volume 17, Issue 12 Ver. 4 (December. 2018), PP 49-55.
- [11] Cohn SM, Giannotti G, Ong AW, Varela JE, Shatz DV, Mckenney MG, et al. Prospective randomised trial of two wound management strategies for dirty abdominal wounds. *Ann Surg* 2001; 233: 409-13.
- [12] Adesunkanmi AR, Ajao OG. Typhoid ileal perforation: The value of delayed primary closure of abdominal wounds. *Afr J Med Sci* 1996; 25: 31-5.
- [13] Christopher OB, Primary versus Delayed – primary closure of dirty abdominal wounds in National Postgraduate Medical College of Nigeria (NPMCN) Library; Nov 1991: 84-90.
- [14] Agbakwuru EA, Adesunkanmi AR, Fadiora SO, Olayinka OS, Aderonmu AO, Ogundoyin OO. A review of typhoid perforation in a rural African hospital. *West Afr J Med* 2003; 22: 22-5.
- [15] Duttaroy DD, Jitendra J, Duttaroy B, Bansal U, Dhameja P, Patel G, et al. Management strategy for dirty abdominal incisions: Primary or delayed primary closure? A randomized trial. *Surg Infect (Larchmt)* 2009; 10: 129-36.