

Treatment of a Patient with Ossification of Ligamentum Flavum of Cervical Spine and Literature Review

Ding Ming, Li Chao

Department of Orthopedics, Affiliated Hospital of Qingdao Binhai University, Qingdao, China

Email address:

zbdyyygk@163.com (Ding Ming), lichaguke@163.com (Li Chao)

To cite this article:

Ding Ming, Li Chao. Treatment of a Patient with Ossification of Ligamentum Flavum of Cervical Spine and Literature Review. *Journal of Surgery*. Vol. 9, No. 6, 2021, pp. 282-286. doi: 10.11648/j.js.20210906.16

Received: November 1, 2021; **Accepted:** December 6, 2021; **Published:** December 31, 2021

Abstract: *Background:* The ossification of ligamentum flavum occurs frequently in the thoracic vertebra, and the incidence of ossification of cervical ligamentum flavum is relatively low. It is easy to cause misdiagnosis and mistreatment due to lack of understanding in clinical practice. *Object:* To understand the diagnosis and treatment of cervical ossification of ligamentum flavum through the treatment of one case. *Material:* A 65-year-old female patient was hospitalized due to "lumbar discomfort with numbness of both lower limbs for 1 year, and aggravation with numbness and weakness of both upper limbs for the last 3 months". Physical examination showed cervical flexion, extension and lateral flexion activities were limited, post extension limitations were obvious, limb muscle strength was grade 4, right knee tendon reflex was active, and bilateral Hoffman sign and right Babinski sign were positive. Cervical JOA score was 8 points. Magnetic resonance imaging of cervical spine showed that there were pressure objects protruding to the spinal canal between C3/4, C5/6, and C6/7 laminae. Sagittal MRI showed segmental or focal nodular space occupying and protruding into the spinal canal from the rear of the spinal canal. Cross sectional MRI showed nodular or "M" shaped occupying space. T1 weighted image was equal signal, and T2 weighted image showed low signal shadow, suggesting high-density ossification and severe spinal cord compression. The effective sagittal diameter was less than 8mm. *Method:* Hemilaminectomy was performed for a single segmental OLF of C3/4, and a total laminectomy was performed for bilateral and multi-segmental OLF of C5/6, 6/7. According to the range of intraoperative decompression, C5 and 6 posterior lateral mass screws and C7 pedicle screws were fixed. *Result:* After the operation, the patient indicated that his upper limbs were relaxed, the umbilical horizontal band disappeared, and the muscle strength of his limbs was stronger than that before the operation. She could move freely on the ground, and her holding was more flexible and powerful than before. The postoperative JOA score was 12 points. The postoperative pathological result was fibrous connective tissue and ossification. The follow-up JOA score was increased to 15 points 8 months after operation, and the improvement rate was 78%. The patient could completely take care of herself, and the treatment was satisfactory. *Conclusion:* Surgical resection of cervical olf and canal decompression is an effective method for the treatment of Cervical OLF and can achieve good clinical results.

Keywords: Cervical Vertebrae, Ligamentum Flavum, Ossification, Heterotopic

1. Introduction

Ossification of ligamentum flavum (OLF) affects middle-aged and elderly patients. The incidence of OLF is higher in people aged 50 ~ 60 years, more commonly observed in men than women, and the incidence tends to increase with age. Ohara *et al.* reported that the incidence of OLF was 3.8% ~ 26.0% [1]. OLF can occur in cervical, thoracic and lumbar vertebrae, most in thoracic vertebrae, and rare in lumbar and cervical vertebrae. It is generally believed that the

mechanism of OLF is related to local biomechanics, metabolism, and genetic factors [2, 3]. Cervical OLF is common in the middle and lower cervical spine, most common at C₅/C₆, followed by C₄/C₅ and C₆/C₇. The lesion range is mostly 1–2 segments. In the same segment, the incidence of bilateral lesions is similar to that of unilateral lesions, and unilateral lesions are more common on the left. The main manifestation of cervical OLF is spinal cord compression caused by spinal canal stenosis, such as limb pain, numbness, and weakness, which has a great impact on

work and life of patients. Patients with mild symptoms can be treated with non-surgical treatment, including neck bracing, drug treatment, etc. For patients with obvious symptoms of spinal cord compression, such as limb sensation, abnormal muscle strength, unstable walking, etc., surgical treatment is recommended. Complete removal of thickened and ossified ligamentum flavum is an effective measure to relieve compression and restore spinal cord function. The surgical methods include laminectomy and internal fixation or laminoplasty with enlarged spinal canal [4]. Such a case was admitted to our hospital. The diagnosis and treatment process are reported as follows.

2. Case Data and Diagnosis and Treatment Process

2.1. Material

The patient, a 65-year-old female, was hospitalized due to "lumbar discomfort with numbness of both lower limbs for 1 year, and aggravation with numbness and weakness of both upper limbs for the last 3 months". In the last year, she was diagnosed as "lumbar spinal stenosis" in the Department of Orthopedics and Traumatology of Traditional Chinese Medicine. After massage, dehydration and treatment with neurotrophic drugs, the symptoms were relieved. In recent 3 months, the symptoms were aggravated, accompanied by numbness and weakness of both upper limbs, clumsy holding objects, unstable walking of both lower limbs, and a sense of girdle at the navel level.

2.2. Physical Examination

The activities of cervical flexion, extension and lateral flexion were limited, the back extension was obviously limited, the lumbar back extension was limited, and the quadriceps femoris and gastrocnemius muscles of both lower limbs were slightly atrophied. The muscle strength of elbow flexion, wrist extension and elbow extension of both upper limbs was grade 4, and the muscle strength of hand grip was grade 4. Hip flexion, knee flexion and extension and dorsum flexor muscle strength of both lower limbs were grade 4. The upper limbs felt symmetrical and normal, and the lower limbs and saddle area felt hypoesthesia from below the umbilicus. The right knee tendon reflex was active, and the bilateral Hoffman sign and the right Babinski sign were positive. The cervical JOA score was 8 points.

2.3. Imaging Findings

X-ray film showed cervical degenerative change. Cervical CT showed ossification of the posterior ligamentum flavum at C3/4, C5/6 and C6/7 segments. C3/4 showed ossification of the unilateral (left) ligamentum flavum, and C5/6 and C6/7 showed ossification of the bilateral ligamentum flavum, which was basically symmetrical on both sides (Figure 3). The ossified ligamentum flavum protruded into the spinal canal, and the corresponding horizontal spinal canal was

narrow. The median sagittal diameter of the spinal canal was measured by CT in the cross section. The narrowest median sagittal diameter of the spinal canal was 8mm. Ratio of the narrowest median sagittal diameter of vertebral canal to the median sagittal diameter of corresponding vertebral body [5] (α) was 0.43–0.75 (0.59 ± 0.12). MRI of cervical spine showed that there were protrusions to the spinal canal between C3/4, C5/6 and C6/7 laminae. Sagittal MRI showed segmental or focal nodular occupying space, protruding into the spinal canal from the rear of the spinal canal, and cross-sectional MRI showed nodular or "M" shaped occupying space. T1 weighted image was equal signal, T2 weighted image showed low signal shadow, suggesting high-density ossification, severe compression of spinal cord, effective sagittal diameter < 8mm, and mild degeneration of spinal cord in compression stage (Figure 1). Lumbar MRI indicated stenosis of spinal canal and lateral recess in L3/4 and L4/5 stages (Figure 2).

2.4. Treatment

After general anesthesia, the patient was placed to the prone position, routinely disinfected, covered with towel, and underwent surgery via the posterior cervical approach. The skin and subcutaneous tissue were cut in turn to expose the corresponding segmental spinous process, lamina, and lateral mass. Hemilaminectomy was performed for a single segmental OLF of C3/4, and a total laminectomy was performed for bilateral and multi-segmental OLF of C5/6, 6/7. The whole laminectomy was performed by grinding drill and ultrasonic osteotome slotting, and the spinal cord was monitored during the operation. Attention was paid to dural adhesion, and a low-dose hormone shock was performed in advance when removing the lamina (100 ml of normal saline containing 1.0 g of methylprednisolone was administered within 15 minutes) to prevent spinal cord injury and reduce reperfusion injury. According to the range of intraoperative decompression, C5 and 6 posterior lateral mass screws and C7 pedicle screws were fixed. After fluoroscopy confirmed that the position of the internal fixator was satisfactory, complete hemostasis was carried out, and we placed the drainage tube, successively sutured fascia, subcutaneous and skin, and wrapped it with sterile dressing. Hormone, dehydration, and neurotrophic drugs were used after operation.

2.5. Results

After operation, the patient expressed that his upper limbs were relaxed, the umbilical horizontal band sensation disappeared, the muscle strength of his limbs grew stronger than that before operation. She could move freely on the ground, and his holding was more flexible and powerful. The neurological function of the patient was evaluated by the Japanese Orthopedic Association (JOA) score [6]. The improvement rate of JOA score (%) = (postoperative JOA score - preoperative JOA score) / (17 - preoperative JOA score) \times 100%. Efficacy evaluation: the improvement rate

of JOA score $\geq 75\%$ is considered excellent, the improvement rate of JOA score $< 75\%$ and $\geq 50\%$ is considered good, the improvement rate of JOA score $< 50\%$ and $\geq 25\%$ is considered fair, and the improvement rate of JOA score $< 25\%$ is considered poor. The JOA score reached 12 points, and the postoperative pathological diagnosis was fibrous connective tissue and ossification (Figure 7). The patients were followed up for 8 months after operation and showed complete decompression and reliable fixation (Figures 8 and 9). The JOA score was raised to 15, and the improvement rate was 78%. The patient could completely take care of her life, and the daily life and work had returned to normal.

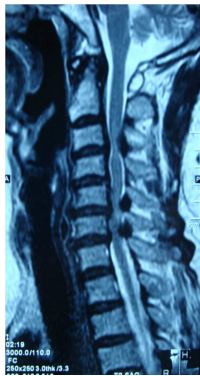

Figure 1. Cervical magnetic resonance (sagittal position).

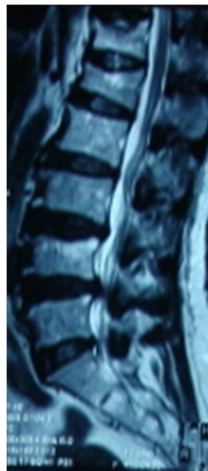

Figure 2. Lumbar magnetic resonance (sagittal position).

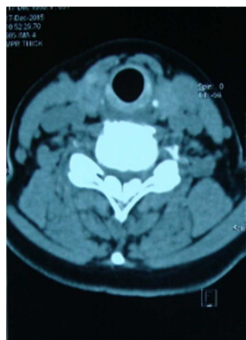

Figure 3. Cervical CT shows ossification of ligamentum flavum.

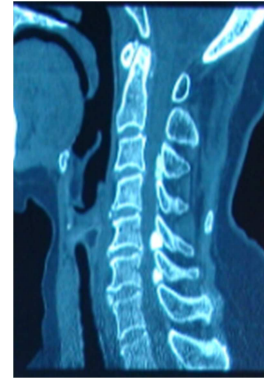

Figure 4. CT of ossification of cervical ligaments (sagittal position).

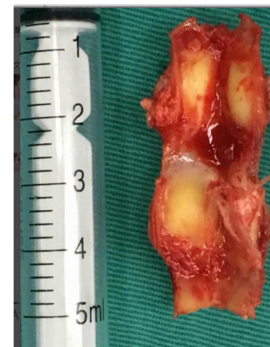

Figure 5. Resection of vertebral canal posterior depressor and lamina during operation.

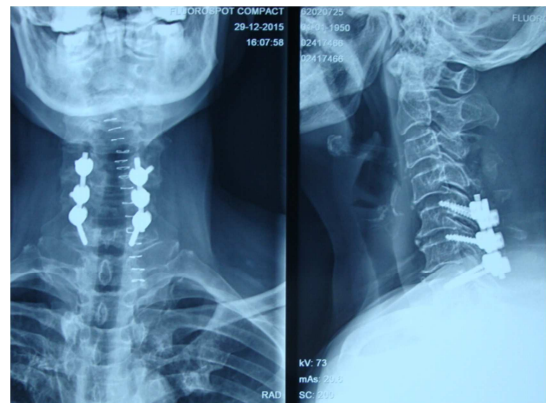


Figure 6. X-ray films after cervical spine surgery (positive and lateral).

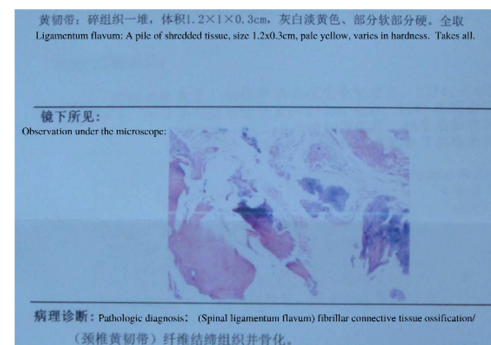


Figure 7. Postoperative pathological results show ossification of ligamentum flavum.

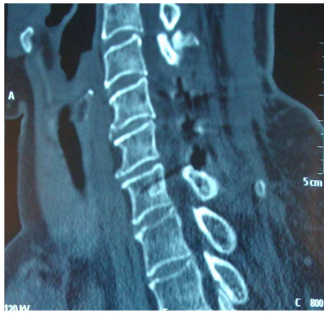

Figure 8. Cervical CT (sagittal position) 8 months after operation.

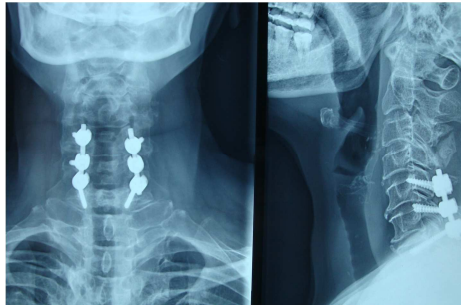


Figure 9. X-ray of cervical spine at 8 months after operation.

Case: female, 65 years old. 1: preoperative sagittal MRI of cervical spine showed C₃/C₄, C₅/C₆/C₇ spinal canal pressure. T1 and T2 weighted images showed low signal, suggesting high-density ossification and severe spinal cord compression. 2: preoperative sagittal MRI of lumbar spine showed L₄/L₅/S₁ spinal canal and lateral recess stenosis. 3: preoperative cross-sectional CT showed C₃/C₄ left OLF, C₅/C₆/C₇ bilateral OLF. 4: preoperative sagittal CT showed cervical OLF, C₄/C₅ segment also showed ossification foci of ligamentum nuchae. 5: total laminectomy of ossified ligamentum flavum performed. 6, 7: postoperative anterior and lateral X-ray film of cervical spine showed reliable internal fixation and good position. 8: postoperative pathological examination showed OLF. 9-10: sagittal CT three-dimensional reconstruction of cervical spine 6 months after operation showed complete decompression of spinal canal, and X-ray film showed reliable internal fixation and good position.

2.6. Conclusion

Surgical resection of the ligamentum flavum for cervical ossification and decompression of the spinal canal are effective methods for the treatment of Cervical OLF, and the surgical treatment of Cervical OLF can achieve good clinical results.

3. Discussion

3.1. Diagnosis

Detailed and comprehensive physical examination and full imaging examination before treatment are the key to the diagnosis of cervical OLF. Cervical OLF causes the lower limb sensation and weakening of muscle strength, which is

easy to be confused with lumbar spinal stenosis [7]. Therefore, in case of hypoesthesia of lower limbs with walking weakness, it is necessary to consider the possibility of cervical degenerative change. In case of suspected damage of upper motor neurons, further examination of cervical spine and thoracic vertebrae should be carried out to clarify the lesion location. MRI alone cannot distinguish between hypertrophy and ossification of ligamentum flavum, and thus CT is the golden standard for diagnosis.

The difference between ossification and calcification mainly lies in the presence or absence of ossification in the tissue. Calcification is mainly caused by calcium salt deposition [8, 9]. It mostly occurs at the points with large ligament tension to enhance or adapt to the tension [9, 10]. Therefore, ossifying lesions should be considered first for multi-level and a wide range of ligament lesions. Small-scale patchy lesions are mostly considered as calcified lesions, and the final diagnosis needs to be based on pathological examination. In this case, the lesions occurred between the lamina, and the lesions were diffuse and involved multiple segments. Therefore, this case was considered as ossifying lesions, which was confirmed as OLF by the postoperative pathological examination of the patient.

3.2. Surgical Treatment

The authors believe that when the symptoms, signs and imaging of OLF are highly consistent and the diagnosis is clear, surgical treatment is the first choice. The cervical ligamentum flavum is located on both sides of the spinal canal, and the median sagittal diameter of the cervical spinal canal cannot represent the severity of the disease but only be used as a reference. The effective volume of the spinal canal is more useful for the evaluation of the severity of the disease. The surgical risk should be carefully evaluated for patients with poor general condition. The spinal cord compression caused by OLF is direct posterior compression, which is different from spinal canal stenosis caused by intervertebral disc herniation and OPLL. It is not recommended to expand the spinal canal and perform laminoplasty for indirect decompression. Direct resection of posterior compression material via posterior cervical approach is the first choice. Hemilaminectomy can be performed for unilateral single segment OLF, which has little impact on the stability of cervical spine, and thus internal fixation is not required. For bilateral and multi-segment OLF, total laminectomy or multiple total laminectomy and decompression are required, which greatly affects the stability of cervical posterior column, and lateral mass screw fixation corresponding to the decompression segment is required [11]. According to the treatment principle of spinal cord injury, hormone is routinely used. Methylprednisolone can be used before laminectomy in patients with severe spinal stenosis to reduce iatrogenic spinal cord injury, and spinal cord electrophysiological monitoring should be carried out. Because the ossification foci of ligamentum flavum is often continuous with the edge of lamina and adheres to dural sac, the operation should be gentle and careful to prevent spinal

cord injury and cerebrospinal fluid leakage. In case of dural sac injury, surgical repair should be carried out in time.

3.3. Prevention

The cause of the ossification of ligamentum flavum is not clear. It is generally believed that it is closely related to many factors, such as local mechanical factors, metabolic abnormalities, and family heredity. The ossification of ligamentum flavum is frequently observed in areas such as Japan and Southeast Asia, where food is high in carbohydrates and people are with diabetes, suggesting that ossification of ligamentum flavum is related to systemic conditions such as glucose metabolism. Many studies suggested that ossification of ligamentum flavum is actually a part of ossification of spinal ligaments [12, 13]. Other studies also suggested that the disease is related to genetic factors, such as HLA antigen system and ethnic differences. In addition, appropriate posture adjustment, avoiding long-term low head work and play, and appropriate head raising action can reduce the tension of ligamentum flavum and reduce the occurrence of ossification of ligamentum flavum of cervical spine.

The point of view on cervical OLF in this case is similar to that of Sonntag [14]. Due to the low incidence of cervical OLF, there may be bias in clinical manifestations and other diagnosis indicators, and the selection of factors to investigate may be not systematic enough. We expect there will be multi center and large-sample study to analyze OLF systematically in the future.

References

- [1] Ohara Y. Ossification of the ligaments in the cervical spine, including ossification of the anterior longitudinal ligament, ossification of the posterior longitudinal ligament, and ossification of the ligamentum flavum [J]. *Neurosurg Clin N Am*, 2018, 29 (1): 63-68.
- [2] Li huiqing, Xing feng, Wu desheng, et al. Diagnosis and treatment of ossification of cervical ligamentum flavum [J]. *Shanghai Preventive Medicine*, 2011, 23 (3): 138-139.
- [3] Takahashi T, Hanakita J, Minami M. Pathophysiology of calcification and ossification of the ligamentum flavum in the cervical spine [J]. *Neurosurg Clin N Am*, 2018, 29 (1): 47-54.
- [4] Feng liangen, Zhou rongping, Gu yurong, et al. Cervical ossification of ligamentum flavum combined with ossification of posterior longitudinal ligament was treated by stages [J]. *Journal of Practical Orthopedics*, 2014, 20 (11): 961-964.
- [5] Jiang zhensong, Zhang zuolun, Liu lichneg, et al. Cervical CT measurement in patients with cervical spondylotic myelopathy and its clinical significance [J]. *Chinese Journal of Spinal cord*, 2003 (4): 29-32.
- [6] Fukui M, Chiba K, Kawakami M, et al. Japanese Orthopaedic Association Cervical Myelopathy Evaluation Questionnaire (JOACMEQ): Part 2. Endorsement of the alternative item [J]. *J Orthop Sci*, 2007, 12 (3): 241-248.
- [7] Feng FB, Sun CG, Chen ZQ. Progress on clinical characteristics and identification of location of thoracic ossification of the ligamentum flavum [J]. *Orthop Surg*, 2015, 7 (2): 87-96.
- [8] Tetreault L, Goldstein CL, Arnold P, et al. Degenerative cervical myelopathy: a spectrum of related disorders affecting the aging spine [J]. *Neurosurgery*, 2015, 77 (Suppl 4): S51-67.
- [9] Liu zhongjun, Cai qinlin, Dang gengting, et al. Ossification and calcification of the ligamentum flavum of the cervical spine [J]. *Chinese Journal of Spinal cord*, 1996, (2): 11-13.
- [10] Song JY, Park JH, Roh SW. Ossified Ligamentum Flavum causing Cervical Myelopathy [J]. *Korean J Spine*, 2012, 9 (1): 24-27.
- [11] Jia lianshun, Shi jiangang. Pay attention to the diagnosis and strict operation indication of cervical spondylotic myelopathy [J]. *Chinese Journal of Orthopaedics*, 2002, 22 (1): 58-60.
- [12] Kotani Y, Takahata M, Abumi K, et al. Cervical myelopathy resulting from combined ossification of the ligamentum flavum and posterior longitudinal ligament: report of two cases and literature review [J]. *Spine J*, 2013, 13 (1): e1-e6.
- [13] Paiva WS, Soares MS, Bernardo LS, et al. Cervical myelopathy caused by ligamentum flavum ossification [J]. *Arq Neuropsiquiatr*, 2012, 70 (1): 71-72.
- [14] Sonntag VK. Ossification of the ligamentum flavum (OLF): an increasing cause of cervical myelopathy [J]. *World Neurosurg*, 2011, 75 (3-4): 445-446.