

Use of Anti-coagulants in Cancer Patients with Superficial Thrombophlebitis to Prevent Pulmonary Embolism

Pratikkumar Vekaria^{1,*}, Mansi Satasia³, Tejas Raiyani¹, Rekha Rao², Chandrika Raiyani¹, Kevin Dan Phillips¹

¹Redmond Regional Medical Center, Rome, United States

²Frederick National Laboratory for Cancer Research, Frederick, United States

³Department of Dermatology, Byramjee Jeejabhoy Medical College, Ahmedabad, India

Email address:

drpratikkvekaria11@gmail.com (P. Vekaria)

*Corresponding author

To cite this article:

Pratikkumar Vekaria, Mansi Satasia, Tejas Raiyani, Rekha Rao, Chandrika Raiyani, Kevin Dan Phillips. Use of Anti-coagulants in Cancer Patients with Superficial Thrombophlebitis to Prevent Pulmonary Embolism. *World Journal of Medical Case Reports*.

Vol. 2, No. 3, 2021, pp. 35-40. doi: 10.11648/j.wjmcr.20210203.12

Received: September 20, 2020; Accepted: July 12, 2021; Published: July 21, 2021

Abstract: Superficial thrombophlebitis (STP) is an inflammation of superficial veins with associated venous thrombosis. It is a benign condition usually and can be managed with a conservative approach with non-steroidal anti-inflammatory drugs (NSAIDs) and warm compression. When STP is associated with high-risk medical conditions such as cancer and chemotherapy, fatal complications such as pulmonary embolism (PE) and deep venous thrombosis (DVT) may ensue. The severity of thromboembolic complications of STP as well as the multiple common risk factors between DVT and STP has led to further research interest in exploring the efficacy of anticoagulation treatment in DVT and STP. Traditionally, low molecular weight heparin (LMWH) and warfarin have been used for the treatment of venous thromboembolism (VTE), but recently direct oral Anticoagulants (DOACs) have emerged as a potential alternative considering better or equivalent efficacy, safety, and ease of use compared to LMWH and warfarin. A few case reports have described the advancement of STP to PE in cancer patients while on chemotherapy. We report a case of a 56-year old female with colon cancer on chemotherapy who developed PE after two episodes of STP. We recommend that when cancer patients on chemotherapy develop STP, prophylactic use of anti-coagulants should be considered to reduce the risk of serious complications.

Keywords: Superficial Thrombophlebitis, Pulmonary Embolism, Chemotherapy, Cancer, Anticoagulant

1. Introduction

Superficial veins are located just beneath the dermis and when inflammation occurs, thrombi may develop and present as superficial thrombophlebitis (STP) or superficial venous thrombosis (SVT). The patient typically presents with painful erythematous, warm, and tender cord-like lesions extending along the vein with surrounding edema or pruritus [1]. STP affects from 3 to 11% of the general population [2]. In the US, the prevalence of STP is reported as 123,000 cases per year by Conn et al [3]. Usually presenting in the lower extremities, STP most often affects the tributaries of the great saphenous vein. STP can advance into deep venous thrombosis (DVT) or pulmonary embolism (PE) by migration of a thrombus towards the deep veins at the

saphenopopliteal or saphenofemoral junction, especially, in the hypercoagulable state [4, 5]. An earlier study showed that 43 out of 50 patients who had STP of the great saphenous vein developed PE [6]. Management is usually conservative mainly focusing on relieving the local symptoms with warm-compression and NSAIDs [7]. When it involves the main trunk of the saphenous vein, it is treated more aggressively to prevent proximal extension to the deep venous system [8]. Up to 40% of proximal DVT can convert to PE and around 70% of cases of PEs are associated with DVT in the lower extremities [9]. Patients with hypercoagulability are more likely to develop DVT compared to the general population [10]. Hypercoagulability is commonly associated with genetic disorders, medications, chemotherapy, malignancy, and other medical conditions. Patients with cancer tend to

produce fibrinolytic and pro-coagulants factors which can lead to a hypercoagulable state [11]. There is a proven association between STP and malignancy, like trousseau's syndrome seen in pancreatic cancer and Mondor disease [12]. Hence, patients with STP in the setting of malignancy should be approached aggressively to prevent serious outcomes like Venous-thromboembolism (VTE); i.e. DVT and PE. Anti-coagulants are effective to both prevent and treat VTE. Warfarin and low-molecular-weight heparin (LMWH) are traditional agents used for VTE treatment. However, direct oral anticoagulants (DOACs) have been approved recently due to their safety profile and reduced need for regular check-ups compared to vitamin K antagonists.

2. Case Presentation

A 56 years old Caucasian female with a past medical history of adenocarcinoma of the colon status post resection on adjuvant chemotherapy presented to the emergency department with right-sided chest pain. The patient had no shortness of breath or other cardiac symptoms. The patient was afebrile with a heart rate of 100, respiratory rate of 16, and blood pressure of 115/81 mm Hg. Electrocardiogram did

not show significant acute ST-segment or T wave changes. CT of the chest with contrast was significant for right upper and lower lobe pulmonary embolism. 2 months prior to these symptoms, the patient had finished her 2nd cycle of chemotherapy with Capecitabine and developed right lower extremity erythema and tenderness along the ankle and lower inner leg. The patient was treated with conservative management for STP with NSAIDs and reported resolution of symptoms in 2 days. However, after the patient's next chemotherapy cycle, she developed similar symptoms. Doppler ultrasound of the right lower extremity was repeated, which demonstrated no intra-luminal filling defect or evidence for DVT. The patient was started on low-dose Aspirin. Approximately 11 days later, after another cycle of chemotherapy, the patient presented with acute pulmonary embolism. A trans-thoracic echocardiogram demonstrated normal left ventricular function with no evidence of right heart strain. The patient was started on Apixaban – a DOAC agent. Repeat chest CT with contrast was performed after a month which revealed resolution of pulmonary embolism as shown in images below. The patient completed her remaining chemotherapy cycles successfully without recurrence of VTE.

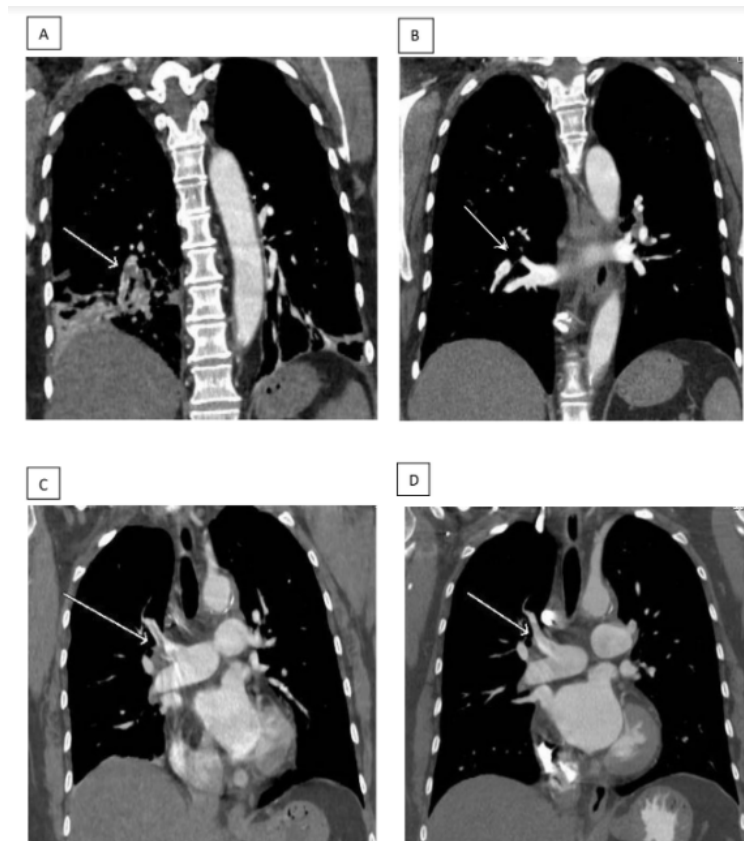


Figure 1. Image A. CT chest with contrast (Coronal view): Arrow shows the presence of Right Lower Lobe PE. Image B. CT chest with contrast (Coronal view): Arrow shows resolution of Right Lower Lobe PE. Image C. CT chest with contrast (Coronal view): Arrow shows the presence of Right Upper Lobe PE. Image D. CT chest with contrast (Coronal view): Arrow shows resolution of Right Upper Lobe PE.

3. Discussion

Superficial thrombophlebitis (STP) can be described as an

inflammatory reaction along the course of a superficial vein with partial occlusion of the lumen from the thrombus. The factors that are critically important in the development of

STP include Virchow's triad: hypercoagulability, static blood flow, and endothelial injury [13]. A varicose vein is one of the most common causes of STP, and it can lead to stasis, inflammation, and thrombosis because of its dilatation and tortuosity. Other causes are Traumas, injection of irritants, immunological diseases (Lemierre, Trousseau, or Mondor syndromes), or inflammatory diseases such as thromboangiitis obliterans [14]. It has been considered a benign medical condition and is usually managed conservatively without systemic anticoagulation. Occasionally, there could be more serious implications of STP. Previous research has shown that 10% to 17% of patients could develop pulmonary embolism as a result of STP near the saphenofemoral junction [15]. Another study validates this finding and suggested that 33% of patients with STP of a greater saphenous vein (thigh), without apparent concurrent deep venous thrombosis, could progress to pulmonary embolism [8]. In selected patients, STP may not be a benign condition [16].

Many factors affect the risk of STP progression to VTE, including age, sex, location (above-knee or below-knee), overall health condition, medications, and a coagulation profile [11, 15, 17]. Literature also showed that 12% to 40% of cases of STP are associated with occult deep venous thrombosis (DVT) and PE [10, 18]. The risk of PE is similar to that of DVT, especially if STP is present within 3 cm from a saphenofemoral junction, and the study recommends considering anticoagulation in such cases (Evidence level 2B) [19, 20]. Though SVT is a straightforward clinical diagnosis, supplementary investigations are required to confirm the extension of thrombus and possible thromboembolic complications. To avoid these complications, it is crucial to implement effective diagnostic and therapeutic strategies quickly. Compressive ultrasonography could be considered in high-risk patients with increasing evidence of association with concomitant DVT or PE [21, 22, 5]. D-dimer testing has a limited role in detecting STP. It can be inconsistently increased in SVT, and cannot be used to differentiate between isolated STP and DVT [21]. Therefore, a non-invasive diagnostic method like doppler ultrasound has been recommended in patients with STP to rule out occult DVT [18].

Superficial thrombophlebitis can also be associated with malignancy affecting the balance between coagulation and fibrinolysis [23]. Among 60 to 70% of cases of STP involving the great saphenous vein that is not varicose, 5 to 13% of cases may be associated with cancer [24-27]. STP is most commonly associated with adenocarcinoma of the pancreas, colon cancer, breast malignancies, hematological malignancies, and skin cancer. [21, 28] In cancer, tumors can compress veins, and resulting in venous stasis can also increase the risk of thrombosis. Cancer patients are twice at risk of developing lower limb DVT, and a four-fold risk of growing post-operative PE than non-cancer patients [29, 30]. VTE is the second commonest cause of mortality in cancer patients [31]. There have been increasing incidences of thromboembolic deaths in cancer, especially carcinoma of

the pancreas (mucinous), lung, and gastrointestinal tract as shown by many postmortem studies [32]. Tumor cells produce pro-coagulant factors that can trigger the coagulation cascade or indirectly, increase the thrombogenic properties of the different components of blood. Apart from cancer itself, its treatment modalities including surgery, hormonal therapy, cytotoxic chemotherapy can initiate clotting activation and pose a risk for VTE [33-37]. Chemotherapy itself can accelerate the likelihood of developing thromboembolic events, especially in patients with venous catheters [17].

The STP treatment goals are a) symptomatic relief (reduce inflammation of an affected vein and surrounding tissue); b) prevent extension of thrombus along with the superficial vein system and/or into the deep system; c) prevent recurrence, and d) prevent thromboembolic complications (DVT and PE). Multiple case studies have suggested that STP should be managed cautiously when associated with high-risk factors such as STP at or near a saphenous-femoral junction or in cancer patients on chemotherapy [15, 17]. Treatment options ranging from nonpharmacological advice (walking, rest in the Trendelenburg position), topical treatments (warm compressions, anti-inflammatories, and elastic compression), systemic (anti-inflammatories, heparins, vitamin K antagonists, factor Xa inhibitors, and direct thrombin inhibitors), to surgical interventions (ligature of the great saphenous and saphenectomy). Of note, endogenous heparin plays an important role in cancer-associated thrombosis. Overexpression and secretion of heparanase (an enzyme that degrades heparin) by tumor cells culminates into endogenous heparin degradation and hypercoagulability. [38]

Pharmacological management options for VTE include unfractionated heparin, LMWHs, coumadin, fondaparinux (an indirect synthetic inhibitor of activated factor Xa), and DOACs, including; dabigatran (direct thrombin inhibitors), and apixaban, edoxaban, and rivaroxaban (direct factor Xa inhibitors) [39, 40]. LMWH had shown an advantage over oral coumadin derivative in terms of efficacy, recurrence of VTE, and a risk of bleeding in patients with cancer and acute VTE [41]. The heparanase-inhibiting function leverages this advance to LMWH [46]. LMWH is considered the current standard-of-care treatment for cancer-associated VTE [47]. Multiple studies have shown mortality benefits of using heparin and LMWH for VTE in cancer patients [41, 42, 44, 45]. The American College of Chest Physicians (ACCP) consensus guidelines recommend prophylactic use of fondaparinux or LMWH for 45 days in patients with STP of at least 5 cm in length, specifically in the lower extremities. Literature also suggested the use of Fondaparinux over prophylactic LMWH considering higher quality evidence [43]. Co chrane's review published in 2018 suggested that high-risk patients (STP proximal to the knee, at least 5 cm in length, within 10 cm of the saphenofemoral junction, greater saphenous vein involvement, the presence of severe symptoms, active malignancy, previous STP/venous thromboembolic disease or recent surgery) should receive subcutaneous fondaparinux 2.5 mg per day for 45 days [1]. Recently, DOACs have been increasingly acknowledged as

potential alternative to LMWH due to their effectiveness, safety profile, and convenience- leading to greater compliance. With DOACs, patients don't need frequent blood testing as they do with warfarin [46, 47]. One study showed that DOACs such as Rivaroxaban as an effective and safe anti-coagulant when considering major bleeding, recurrence, and mortality [49, 50]. Recent meta-analysis also showed superiority of DOACs in terms of treatment and recurrence of VTE in cancer patients compared to LMWH [50, 51]. Furthermore, cancer patients receiving chemotherapy are specifically at high risk for VTE [52]. Their risk of developing VTE can be identified by The Khorana risk score (KRS), a validated risk stratification tool [23]. Studies showed that in high-risk patients (with a KRS score of ≥ 2), apixaban and rivaroxaban reduce the incidence of VTE [53, 54].

Further studies are needed to optimize the duration of the new oral anti-coagulants class for the prevention of VTE in patients with STP with the aforementioned risk factors.

4. Conclusion

We report a case of superficial thrombophlebitis in a colon cancer patient on chemotherapy who developed pulmonary embolism during conservative treatment. Patients with cancer, and those on chemotherapy, are at greater risk for VTE and if they develop STP due to various medical conditions, the chances of developing DVT and PE increase significantly. Several case reports support the treatment with anti-coagulant in these patients who develop STP to prevent advancement to VTE. Thus, our case report suggests starting an appropriate anticoagulant therapy such as LMWH, warfarin, or DOACs as soon as possible to prevent thromboembolic complications in these patients.

Future consideration: The use of DOACs can be employed if future studies confirm their promise in the prophylaxis and treatment of thromboembolic diseases in the setting of malignancy.

Disclaimer

This research was supported (in whole or in part) by HCA Healthcare and/or an HCA Healthcare affiliated entity. The views expressed in this publication represent those of the author(s) and do not necessarily represent the official views of HCA Healthcare or any of its affiliated entities.

References

- [1] Di Nisio M, Wickers IM, Middeldorp S. Treatment for superficial thrombophlebitis of the leg. *Cochrane Database Syst Rev*. 2018 Feb 25; 2: CD004982.
- [2] Schonauer V, Kyrle PA, Weltermann A, Minar E, Bialonczyk C, Hirschi M, et al. Superficial thrombophlebitis and risk for recurrent venous thromboembolism. *J Vasc Surg* 2003 Apr; 37 (4): 834e8.
- [3] Coon WW, Willis PW 3rd, Keller JB. Venous thromboembolism and other venous disease in the Tecumseh community health study. *Circulation*. 1973; 48 (4): 839-46. <http://dx.doi.org/10.1161/01.CIR.48.4.839>. PMID: 4744789.
- [4] Décousus H, Bertolotti L, Frappé P. Spontaneous acute superficial vein thrombosis of the legs: do we really need to treat? *J Thromb Haemost*. 2015 Jun; 13 Suppl 1: S230-7.
- [5] Scott G, Mahdi AJ, Alikhan R. Superficial vein thrombosis: a current approach to management. *Br J Haematol*. 2015 Mar; 168 (5): 639-45.
- [6] Markovic MD, Lotina SI, Davidovic LB, et al. Acute superficial thrombophlebitis: modern diagnosis and therapy. *Srp Arch Celok Lek* 1997; 125: 261-6.
- [7] Vekaria, Pratikkumar MD; Raiyani, Chandrika MD; Robitshek, Daniel MD; Raiyani, Tejas MD 3074 In Colon Cancer: Superficial Thrombophlebitis Is a Road to PE, *The American Journal of Gastroenterology*: October 2019 - Volume 114 - Issue - p S1654-S1655 doi: 10.14309/01.ajg.0000601828.04642.2b.
- [8] Verlato F, Zucchetto P, Prandoni P, et al. An unexpectedly high rate of pulmonary embolism in patients with superficial thrombophlebitis of the thigh. *J Vasc Surg* 1999; 30: 1113-15.
- [9] Wilbur J, Shian B. Diagnosis of deep venous thrombosis and pulmonary embolism. *Am Fam Physician*. 2012; 86 (10): 913-919.
- [10] Bounameaux H, Reber-Wasem MA. Superficial thrombophlebitis and deep vein thrombosis: a controversial association. *Arch Intern Med* 1997; 157: 1822.
- [11] Caine GJ, Stonelake PS, Lip GY, Kehoe ST. The Hypercoagulable State of Malignancy: Pathogenesis and Current Debate. *Neoplasia* (New York, NY). 2002; 4 (6): 465-473.
- [12] Varki A. Trousseau's syndrome: multiple definitions and multiple mechanisms. *Blood*. 2007; 110 (6): 1723-1729.
- [13] Dickson B. C. Venous thrombosis: On the history of Virchow's triad. *Univ. Tor. Med. J*. 2004; 81: 166-171.
- [14] Sobreira ML, Yoshida WB, Lastória S. Tromboflebite superficial: epidemiologia, fisiopatologia, diagnóstico e tratamento. *J Vasc Bras*. 2008; 7 (2): 131-43.
- [15] Ascer E, Loresen E, Pollina RM, Gennaro M. Preliminary results of a non-operative approach to saphena femoral junction thrombophlebitis. *J Vasc Surg*, 22 (1995), pp. 616-621.
- [16] Blumenberg RM, Barton E, Gelfand ML, Skudder P, Brennan J. Occult deep vein thrombosis complicating superficial thrombophlebitis. *J Vasc Surg* 1998; 27: 338-43.
- [17] Frederick R. Rickles, Mark Levine, Richard L. Edwards. Hemostatic alterations in cancer patients. *Cancer and Metastasis Reviews*, 1992, Volume 11, Number 3-4, Page 237.
- [18] Jorgensen JO, Hanel KC, Morgan AM, Hunt JM. The incidence of deep vein thrombosis in patients with superficial thrombophlebitis of the lower limbs. *J Vasc Surg* 1993; 18: 70.
- [19] Decousus H, Epinat M, Guillot K, Quenet S, Boissier C, Tardy B. Superficial vein thrombosis: risk factors, diagnosis, and treatment. *Curr Opin Pulm Med*. 2003; 9 (5): 393-7.

- [20] Leizorovicz A, Becker F, Buchmuller A, Quéré I, Prandoni P, Decousus H. Clinical relevance of symptomatic superficial-vein thrombosis extension: lessons from the CALISTO study. *Blood*. 2013; 122 (10): 1724-9.
- [21] Nasr H, Scriven JM. Superficial thrombophlebitis (superficial venous thrombosis). *BMJ*. 2015 Jun 22; 350: h2039.
- [22] Tait C, Baglin T, Watson H, Laffan M, Makris M, Perry D, Keeling D., British Committee for Standards in Haematology. Guidelines on the investigation and management of venous thrombosis at unusual sites. *Br J Haematol*. 2012 Oct; 159 (1): 28-38.
- [23] Khorana, A. A., Kuderer, N. M., Culakova, E., Lyman, G. H., Francis, C. W. Development and validation of a predictive model for chemotherapy-associated thrombosis. *Blood*, 2008; 111 (10), 4902-4907.
- [24] Wichers IM, Di Nisio M, Buller HR, Middeldorp S. Treatment of superficial vein thrombosis to prevent deep vein thrombosis and pulmonary embolism: a systematic review. *Haematologica*. 2005; 90 (5): 672-7.
- [25] Leon L, Giannoukas AD, Dodd D, Chan P, Labropoulos N. Clinical significance of superficial vein thrombosis. *Eur J Vasc Endovasc Surg*. 2005; 29 (1): 10-7.
- [26] Milio G, Siragusa S, Mina C, et al. Superficial venous thrombosis: prevalence of common genetic risk factors and their role on spreading to deep veins. *Thromb Res*. 2008; 123 (2): 194-9.
- [27] Decousus H, Quere I, Presles E, et al. Superficial venous thrombosis and venous thromboembolism: a large, prospective epidemiologic study. *Ann Intern Med*. 2010; 152 (4): 218-24.
- [28] Mouton WG, Kienle Y, Muggli B, Naef M, Wagner HE. Tumors associated with supercial thrombophlebitis. *Vasa* 2009; 38: 167-70.20.
- [29] Prandoni P. Antithrombotic strategies in patients with cancer. *Thromb Haemost*. 1997; 78: 141-144.
- [30] Kakkar AK, Williamson RCN. Prevention of venous thromboembolism in cancer patients. *Semin Thromb Haemost*. 1999; 25: 239-243.
- [31] Donati MB. Cancer and thrombosis: from phlegmasia alba dolens to transgenic mice. *Thromb Haemost*. 1995; 74: 278-281.
- [32] Dvorak HF. Abnormalities of haemostasis in malignant disease. In: Colman W, Hirsh J, Marder VJ, Salzman EW, editors. *Haemostasis and Thrombosis*. 3rd edn. Philadelphia, PA: Lippincott; 1994. pp. 1238-1254.
- [33] Luzzato G, Schafer AI. The prethrombotic state in cancer. *Semin Oncol*. 1990; 17: 147-158.
- [34] Levine MN. Prevention of thrombotic disorders in cancer patients undergoing chemotherapy. *Thromb Haemost*. 1997; 78: 133-136.
- [35] Lee AYY, Levine MN. The thrombophilic state induced by therapeutic agents in cancer patients. *Semin Thromb Haemost*. 1999; 25: 137-145.
- [36] Bona R. Thrombotic complications of central venous catheters in cancer patients. *Semin Thromb Haemost*. 1999; 25: 147-155.
- [37] Gallus AS. Prevention of post-operative deep leg vein thrombosis in patients with cancer. *Thromb Haemost*. 1997; 78: 126-132.
- [38] Nasser N. J., Na'amad M., Weinberg I., Gabizon A. A. Pharmacokinetics of low molecular weight heparin in patients with malignant tumors. *Anti-Cancer Drugs*. 2015; 26: 106-111. doi: 10.1097/CAD.0000000000000176.
- [39] Lyman GH, Khorana AA, Kuderer NM, et al; American Society of Clinical Oncology Clinical Practice. Venous thromboembolism prophylaxis and treatment in patients with cancer: American Society of Clinical Oncology clinical practice guideline update. *J Clin Oncol*. 2013; 31 (17): 2189-2204.
- [40] Streiff MB, Holmstrom B, Ashrani A, et al. Cancer-associated venous thromboembolic disease, version 1.2015. *J Natl Compr Canc Netw*. 2015; 13 (9): 1079-1095.
- [41] Lee A. Y., Levine M. N., Baker R. I., Bowden C., Kakkar A. K., Prins M., Rickles F. R., Julian J. A., Haley S., Kovacs M. J., et al. Low-molecular-weight heparin versus a coumarin for the prevention of recurrent venous thromboembolism in patients with cancer. *N. Engl. J. Med*. 2003; 349: 146-153. doi: 10.1056/NEJMoa025313.
- [42] Kakkar A. K., Levine M. N., Kadziola Z., Lemoine N. R., Low V., Patel H. K., Rustin G., Thomas M., Quigley M., Williamson R. C. Low molecular weight heparin, therapy with dalteparin, and survival in advanced cancer: The fragmin advanced malignancy outcome study (FAMOUS) *J. Clin. Oncol.* 2004; 22: 1944-1948. doi: 10.1200/JCO.2004.10.002.
- [43] Kearon C, Akl EA, Comerota AJ, et al; American College of Chest Physicians. Antithrombotic therapy for VTE disease: Antithrombotic Therapy and Prevention of Thrombosis, 9th ed: American College of Chest Physicians Evidence-Based Clinical Practice Guidelines. *Chest*. 2012; 141 (suppl 2): e419S-e494S.
- [44] Lebeau B., Chastang C., Brechot J. M., Capron F., Dautzenberg B., Delaisements C., Mornet M., Brun J., Hurdebourcq J. P., Lemarie E. Subcutaneous heparin treatment increases survival in small cell lung cancer. *Cancer*. 1994; 74: 38-45. doi: 10.1002/1097-0142(19940701)74: 1<38: AID-CNCR2820740108>3.0.CO; 2-E.
- [45] Lazo-Langner A., Goss G., Spaans J., Rodger M. The effect of low-molecular-weight heparin on cancer survival. A systematic review and meta-analysis of randomized trials. *J. Thromb. Haemost*. 2007; 5: 729-737. doi: 10.1111/j.1538-7836.2007.02427.x.
- [46] Vekaria, Pratikkumar MD; Raiyani, Chandrika MD; Robitshek, Daniel MD; Raiyani, Tejas MD 1374 Pancreatic Cancer: Leading to Failure of Rivaroxaban as an Anticoagulant, *The American Journal of Gastroenterology*: October 2019 - Volume 114 - Issue - p S760-S761. doi: 10.14309/01.ajg.0000595024.63908.44.
- [47] Song AB, Rosovsky RP, Connors JM, Al-Samkari H. Direct oral anticoagulants for treatment and prevention of venous thromboembolism in cancer patients. *Vasc Health Risk Manag*. 2019 Jun 21; 15: 175-186. doi: 10.2147/VHRM.S132556. PMID: 31417269; PMCID: PMC6593743.
- [48] Christine G. Kohn, Gary H. Lyman, Jan Beyer-Westendorf, Alex C. Spyropoulos, Thomas J. Bunz and Craig I. Coleman. Effectiveness and Safety of Rivaroxaban in Patients with Cancer-Associated Venous Thromboembolism. *Blood*, 2017; 130: 3717.

- [49] Giustozzi M, Agnelli G, Del Toro-Cervera J, Klok FA, Rosovsky RP, Martin AC, Herold J, Tzoran I, Szmit S, Bertolotti L, Becattini C, Huisman MV. Direct Oral Anticoagulants for the Treatment of Acute Venous Thromboembolism Associated with Cancer: A Systematic Review and Meta-Analysis. *Thromb Haemost.* 2020 Jul; 120 (7): 1128-1136. doi: 10.1055/s-0040-1712098. Epub 2020 May 4. PMID: 32365386.
- [50] Yang M, Li J, Sun R, Wang Y, Xu H, Yang B, Wu X, Yu L. Comparison between direct factor Xa inhibitors and low-molecular-weight heparin for efficacy and safety in the treatment of cancer-associated venous thromboembolism: A meta-analysis. *J Cancer Res Ther.* 2019; 15 (7): 1541-1546. doi: 10.4103/jcrt.JCRT_68_19. PMID: 31939435.
- [51] Brunetti ND, Tricarico L, Correale M, De Gennaro L, Santoro F, Ieva R, Di Biase M. Direct oral anticoagulants more effective than low-molecular-weight heparin for venous thrombo-embolism in cancer: an updated meta-analysis of randomized trials. *J Thromb Thrombolysis.* 2020 Aug; 50 (2): 305-310. doi: 10.1007/s11239-019-01974-y. PMID: 31654194.
- [52] Agnelli G, Gussoni G, Bianchini C et al. Nadroparin for the prevention of thromboembolic events in ambulatory patients with metastatic or locally advanced solid cancer receiving chemotherapy: A randomised, placebo-controlled, double-blind study. *Lancet Oncol* 2009; 10: 943– 949.
- [53] Carrier M, Abou-Nassar K, Mallick R et al. Apixaban to prevent venous thromboembolism in patients with cancer. *N Engl J Med* 2019; 380: 711– 719.
- [54] Khorana AA, Soff GA, Kakkar AK et al. Rivaroxaban for thromboprophylaxis in high-risk ambulatory patients with cancer. *N Engl J Med* 2019; 380: 720– 728.