

# Neonatal Hemoperitoneum on Splenic Rupture Associated with Uterine Fundal Pressure (Kristeller Maneuver) at the Pediatric Hospital of Kalembe Lembe

Noel Dodo Lusungu<sup>1,2,\*</sup>, Jean Jacques Kalongo<sup>1,3</sup>, Gibency Mfulani<sup>3</sup>, Sylvie Ndjoko<sup>1,3</sup>, Faustin Kitetele<sup>4</sup>, Theodore Mbala<sup>1,5</sup>, Catherine Akele<sup>5</sup>, Berthe Barhayiga<sup>2</sup>

<sup>1</sup>Neonatal and Pediatric Surgery Department, Kalembelembe Pediatric Hospital, Kinshasa, DRC

<sup>2</sup>Pediatric Surgery Service of the Department of Surgery of the University Clinics of Kinshasa, Kinshasa, DRC

<sup>3</sup>Department of Anesthesia-Resuscitation, University Clinics of Kinshasa, Kinshasa, DRC

<sup>4</sup>Infectious Diseases Department, Kalembelembe Pediatric Hospital, Kinshasa, DRC

<sup>5</sup>Neonatal Pediatric Kalembelembe Pediatric Hospital, Kinshasa, DRC

## Email address:

[gibencymfulani1990@gmail.com](mailto:gibencymfulani1990@gmail.com) (Noel Dodo Lusungu)

\*Corresponding author

## To cite this article:

Noel Dodo Lusungu, Jean Jacques Kalongo, Gibency Mfulani, Sylvie Ndjoko, Faustin Kitetele, Theodore Mbala, Catherine Akele, Berthe Barhayiga. Neonatal Hemoperitoneum on Splenic Rupture Associated with Uterine Fundal Pressure (Kristeller Maneuver) at the Pediatric Hospital of Kalembe Lembe. *World Journal of Medical Case Reports*. Vol. 4, No. 4, 2023, pp. 44-47. doi: 10.11648/j.wjmc.20230404.11

Received: July 10, 2023; Accepted: August 2, 2023; Published: October 31, 2023

**Abstract:** *Objective:* description of a case of neonatal hemoperitoneum due to splenic rupture after delivery by Kristeller obstetric maneuver in a country with limited resources. *Methods:* This is a clinical observation of a case of neonatal hemoperitoneum due to splenic rupture after vaginal delivery following Kristeller obstetric maneuvers. The newborn presented on the 4th day of life with fever, anemic shock and abdominal distension for which ultrasound exploration showed a hyperechoic fluid collection suggesting peritonitis. Urgent surgical exploration revealed incoagulable blood fluid and a laceration of the spleen with two large hematomas. The surgical procedure consisted of a total splenectomy and aspiration of incoagulable blood. The postoperative course was simple and the newborn was discharged from the hospital on the eighteenth postoperative day. *Conclusion:* neonatal splenic rupture is a rare but serious cause of hemoperitoneum in the newborn

**Keywords:** Newborn, Kristeller Maneuver, Splenic Rupture, Hemoperitoneum, Total Splenectomy

## 1. Introduction

Spontaneous rupture of the normal spleen is a pathology rarely described in the neonatal period which can manifest as intra-abdominal hemorrhage (hemoperitoneum), be complicated by hemorrhagic shock and rapidly lead to the death of the newborn [1-6]. The authors report 613 cases of splenic ruptures regardless of age in a systematic literature review from the 1950s to 2011, of which 35 cases were histologically normal spleens, 23 cases were after minor trauma, 327 cases complained of disease under underlying and 112 had occurred following a medical act [7].

fundic pressure described in 1856 by Samuel Kristeller in which he specified the said technique which involves the

application of manual pressure to the upper part of the uterus directed towards the birth canal in an attempt to shorten the second stage of labor [8]. However, the role of this maneuver in managing the second stage of labor is understudied and remains controversial. In some western, mainly English-speaking countries, it is considered an obsolete maneuver due to intense forensic aspects and undesirable outcomes [9, 10]. A large number of clinical investigations have established that Kristeller's maneuvers can cause major damage to both the mother and the fetus [8].

While in developing countries, particularly in the Democratic Republic of Congo, the procedure seems to be routine practice during vaginal delivery. Through this observation, we want to emphasize the importance in the early recognition of this rare

lesion in the neonatal period which is potentially fatal, particularly in our less equipped hospital settings.

## 2. Clinical Observation

Our neonatology intensive care unit at the Pediatric Hospital of Kalembe Lembe had received a 4-day-old newborn transferred from a maternity ward for fever, mucocutaneous pallor and refusal to suckle. He was a male neonate who weighed 3450 grams at birth with an Apgar of 7, 8 and 9 respectively at the first, fifth and tenth minute of life. He was born of a well-monitored pregnancy, at term of 39 weeks of gestation, from a mother parous 5 and procedure 6 by vaginal route after the Kristeller Maneuver.

The physical examination had noted a lethargic newborn, febrile at 38.6°C, sub-icteric and presenting mucocutaneous pallor. He was tachycardic at 178 beats and polypneic at 64 cycles per minute, his abdomen was bloated, distended with weak peristalsis (Image1). The hypotheses of non-tolerated anemia and neonatal infection were retained. The complete blood count performed was mainly disturbed by a low hemoglobin level at 7g/dl and a high C-reactive protein at 48 mg/l. He was O rhesus positive, his mother too.

Management was marked essentially by transfusion of red blood cells, a triple antibiotic therapy consisting of amoxicillin-cefotaxime-amikacin.

The evolution was marked by a slight improvement in vital signs 18 hours after the blood transfusion. The persistence of abdominal bloating and the recrudescence of anemia (control hemoglobin was 6 g/dl) with disturbance of vital signs prompted the request for a surgical opinion. The physical examination performed by the surgeon had mainly noted a sloping dullness in addition to the previous examination; and the hypothesis of generalized acute peritonitis was retained.

The abdominal ultrasound performed had noted the presence of a hyperechoic fluid collection suggestive of generalized acute peritonitis. The abdominal scanner had not been carried out for lack of means.

Urgent surgical exploration by supra-umbilical transverse laparotomy was performed under general anesthesia with orotracheal intubation. When the peritoneal cavity was opened, we observed hemoperitoneum estimated at 200 ml and a spleen in its anatomical compartment with a laceration on its hilar surface and two large hematomas (Images 2, 3 and 4). A total splenectomy was performed with aspiration of the effused incoagulable blood fluid (Image5). The postoperative course was simple with first-line surgical wound healing in 10 days. The newborn had returned to the neonatal intensive care unit for further medical care and had been discharged from the hospital on the sixteenth postoperative day with appointments for regular vaccination follow-up (pneumococcal and anti-meningococcal vaccination).

## 3. Discussion

Our observation concerned a male newborn born vaginally

in a city maternity ward after the Kristeller maneuver on the fourth day of life. He was transferred to our neonatology department for management of an anemia that was not tolerated on a background of fever. He was admitted and treated in the neonatology department for anemia and a neonatal infection. Our surgery department was contacted for advice following the occurrence of abdominal bloating and lethargy on a background of anemia and fever. Acute generalized peritonitis was retained as the indication for surgery. It was during surgical exploration through a laparotomy that the diagnosis of neonatal hemoperitoneum on ruptured spleen was made and a total splenectomy was performed. Neonatal hemoperitoneum remains a rare diagnosis and is rarely reported in the literature from developing countries but also in developed countries [3, 4, 11].

Splenic rupture is a less common cause of neonatal hemoperitoneum as it accounts for only 10% of intra-abdominal bleeding lesions [1]. While liver damage is the most common (65%) followed by adrenal damage [1]. This is due to the well-protected position of the spleen in the upper left abdominal quadrant. Hemoperitoneum secondary to splenic rupture most often seems to be due to stretching of the splenorenal ligament generally associated with dystocia and/or difficulty in extraction [3]. During uterine contractions, the liver and spleen are pushed out of the diaphragmatic cavity, putting excessive strain on their supporting ligaments [3]. It is highly probable that difficulties during the application of the Kristeller maneuver during the second phase of the delivery of our observation had caused splenic lesions. Kristeller's maneuver (fundal uterine pressure) is routinely used to shorten the second stage of labor but is currently controversial due to its effects on labor, the mother, and the newborn [12]. In some Western countries, it is considered obsolete due to intense forensic aspects and undesirable outcomes [9]. While in developing countries, the procedure seems to be routine practice during vaginal delivery [9]. Some authors argue that a significant amount of data on maternal-fetal damage from this Kristeller maneuver or fundal pressure are unpublished due to forensic implications [8]. Other authors suggest that spontaneous rupture of a previously normal spleen without notion of minimal trauma is possible, but this eventuality is very rarely described [7]. Other rare causes of splenic rupture have been described (taking antiepileptics: phenobarbital, erythroblastosis fetalis and sometimes an intrinsic pathology: mucopolysaccharidosis) [13, 14]. However, obstructed labor remains the primary cause of neonatal splenic rupture [3, 13, 14].

The revealing picture of hemoperitoneum on splenic rupture is often misleading [13]. In our observation, the newborn presented no problem at birth and was discharged from the home maternity ward on the second day of life. He had returned there on the fourth day of life for a picture of anemia and fever. Observation of this evolution in two stages, also made by Grandvuillemin *et al.*, [13].

This misleading picture of neonatal hemoperitoneum is

explained by some authors as a phenomenon resulting from the formation of an almost asymptomatic subcapsular hematoma which is followed a few hours or even a few days later by a sudden capsular rupture responsible for a state hemorrhagic shock [4, 6, 7, 13]. This misleading picture had made the diagnosis and management of our newborn difficult. Some authors maintain that the diagnosis of intra-abdominal bleeding in the neonatal period is difficult, often made at autopsy [3, 11]. Its prognosis therefore depends on the rapidity of the diagnosis and the therapeutic management [1].

The clinical triad presented by our newborn consisting of anemia, abdominal distension and hemorrhagic shock is the typical clinical picture described by the majority of authors during intra-abdominal hemorrhage in the newborn [3, 5, 11]. However, alongside this typical clinical triad, the presence of fever coupled with the ultrasound result of our observation had oriented the diagnosis towards generalized acute peritonitis. Admittedly, ultrasound is one of the additional examinations in the absence of computed tomography for the development of an intra-abdominal hemorrhage [1]. The ultrasound inexperience in our practice of the rare cases of neonatal intra-abdominal hemorrhage has been the basis of diagnostic confusion.

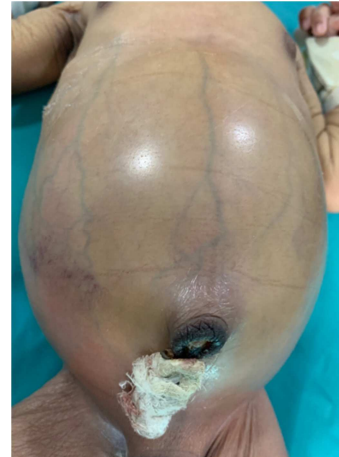Faced with this diagnosis of acute generalized peritonitis, the indication for surgical exploration was imminent. An exploratory laparotomy was performed, during which a significant intra-abdominal hemorrhagic effusion was objectified estimated at 200 ml and a haemostatic total splenectomy was performed. Postoperatively, the newborn was followed in the neonatal intensive care unit with antibiotics and analgesics. His clinical and biological evolution was satisfactory with apyrexia, first-line surgical wound healing and an improvement in blood count parameters.

In France in the years 2003 and 2015, out of approximately one million births, five newborns with hemoperitoneum secondary to splenic rupture were reported. Of these, there was only one neonate who survived after follow-up and eventual total splenectomy. Currently in countries with developed technical platforms, conservative treatment is used in first intention (splenorrhaphy, topical haemostasis by the use of gelatin or absorbable wicks, repair sutures, haemostatic mesh and segmental resection or even autotransplantation [13, 15]. This conservative management, even during laparoscopy which is sometimes arduous, has shown beneficial progress of hemostatic surgery with surgical hemostatic agents [15, 16]. In our observation, the decision to conservative treatment was not possible due to the lack of a technical platform in our workplace. While in 1996, Yamataka et al. reported the case of a successful autotransplantation of splenic fragments in a 2-day-old newborn Conservative therapy including autotransplantation may reduce the duration of antibiotic prophylaxis and the frequency of infections compared to a splenectomized newborn [13, 17].

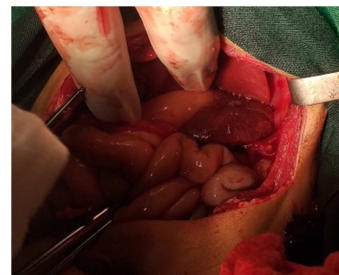
## 4. Conclusion

Neonatal hemoperitoneum secondary to splenic rupture remains a rare surgical emergency associated with high mortality, the vital prognosis of which depends on rapid diagnosis and medico-surgical management.

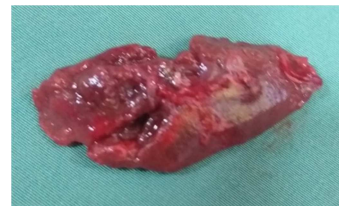## Appendix



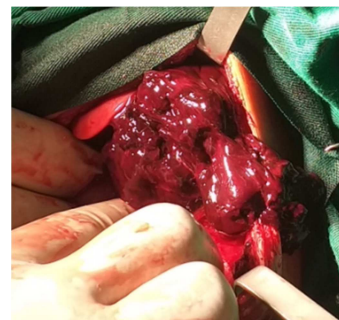**Figure 1.** Abdominal bloating (HPKL).



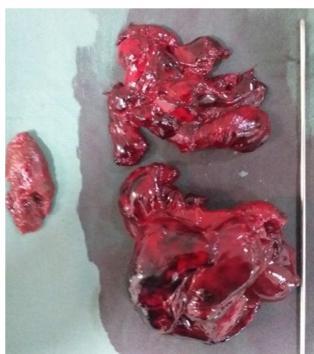**Figure 2.** Hemorrhagic spleen in its compartment (HPKL).



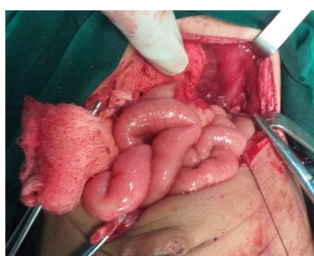**Figure 3.** Hilar face laceration (HPKL).



**Figure 4.** Subcapsular hematomas in the splenic space (HPKL).



**Figure 5.** Parts of the spleen and the 2 large subcapsular hematomas (HPKL).



**Figure 6.** Splenic compartment after total splenectomy (HPKL).

## References

- [1] Claire-Sophie Descamps, Fabrice Cneude, Stephane Hays et al. Early hypovolemic shock and abdominal distention due to neonatal splenic breaking: urgency of diagnosis and management. *Eur J Pediatr* 2017; 176: 1245-50.
- [2] JL Alessandri, A Deschildre, E Daussac et al. Hemoperitoneum and splenic rupture in a newborn infant: case report. *Pediatrics*. 1993; 48 (1): 55-7.
- [3] Jelle W. Raats, Lievay van Dam, Pieter J. van Doormaal et al. Neonatal Rupture of the Spleen: Successful Treatment with Splenic Artery Embolization. *Am J Perinatol rep* 2021; 11:e58–e60.
- [4] Karen Driscoll, Louis C Benjamin, James C Gilbert et al. Non-operative management of neonatal splenic rupture: case report. *Am Surg*. 2004; 70 (12): 1085-7.
- [5] Han-Pi Chang, Ren-Huei Fu, Jainn -Jim Lin et al. Prognosis Factors and Clinical Features of Neonatal Splenic Rupture/Hemorrhage: Two Cases Reports and Literature Review. doi: 10.3389/fped.2021.616247.
- [6] Max Pachl, Khalid Elmalik, Martha Cohen et al. Broken splenic cavernous hemangioma in a neonate. *J Pediatric Surg*. 2008; 43 (2): 407-9.
- [7] Aubrey- Bassler FK, et al. 613 cases of splenic rupture without risk factors or previously diagnosed disease: a systematic review. *BMC EmergMed*. 2012.
- [8] Antonio Malvasi, Simona Zaami, Andrea Tinelli et al. Kristeller maneuvers or fundal pressure and maternal / neonatal morbidity: obstetric and judicial literature review. *The Journal of Maternal-Fetal & Neonatal Medicine*. doi.org/10.1080/14767058.2018.1441278
- [9] Fady M, Shawky Moiety and Amal Z. Fundal pressure during the second stage of labor in a tertiary obstetric center: A prospective analysis. *J. \_ Obst. Gynecol*. 2014; 40 (4); 946–953.
- [10] Youssef A, Salsi G, Cataneo I et al. Fundal pressure in second stage of labor (Kristeller maneuver) is associated with increased risk of lifting ani muscle avulsion. *Ultrasound Obstet Gynecol*. 2019; 53 (1): 95-100.
- [11] Grandvuillemin, G. Emeriaud, C. Jacquier et al. Splenic rupture in the neonatal period: a difficult diagnosis. *j.arcped*.2006; 14: 36–38.
- [12] Bickler S, Ramachandran V, GK Gittes et al. Nonoperative management of newborn splenic injury: a case report. *J. Pediatr Surg*. 2000; 35 (3): 500–501.
- [13] Semra Pinar and Zekiye Karacam. Applying fundal pressure in the second stage of labor and its impact on mother and infant health. *Health Care Women Int*. 2018; 39 (1): 110-125.
- [14] Iatrogenic splenic injury: review of the literature and medico-legal issues.
- [15] Humphrey MR and Castle EP Microporous polysaccharide hemospheres for management of laparoscopy trocar injury to the spleen. *Am. J. Surg*, 2009; 195; 99-103.
- [16] Yamataka, Fujinara T, Tsuchioka T et al. Heterotopic splenic autotransplantation in a neonate with splenic rupture, leading to normal splenic function. *J. Pediatr. Surg*. 1996: 31; 239-240.
- [17] Safae El Abbadi, Fatima Zahra Rhouni, Laila Jroundi et al. Spontaneous splenic rupture: about a case and review of the literature. *Pan Afr Med J*. 2017; 29; 27: 62.